

- 57 Bradley MJ, Spencer PA, Alexander L, Milner GR. Colour flow mapping in the diagnosis of the calf deep vein thrombosis. *Clin Radiol* 1993;47:399–402.
- 58 Baxter GM. The role of ultrasound in deep venous thrombosis. *Clin Radiol* 1997;52:1–3.
- 59 Come PC. Echocardiographic evaluation of pulmonary embolism and its response to therapeutic interventions. Review. *Chest* 1992;101(4 Suppl):151S–62S.
- 60 Konstantinides S, Geibel A, Kasper W. Role of cardiac ultrasound in the detection of pulmonary embolism. *Sem Respir Crit Care Med* 1996;17:39–49.
- 61 Nazeyrollas P, Metz D, Jolly D, Maillier B, et al. Use of transthoracic Doppler echocardiography combined with clinical and electrocardiographic data to predict acute pulmonary embolism. *Eur Heart J* 1996;17:779–86.
- 62 Wolfe MW, Lee RT, Feldstein ML, Parker JA, et al. Prognostic significance of right ventricular hypokinesis and perfusion lung scan defects in pulmonary embolism. *Am Heart J* 1994;127:1371–5.
- 63 Cooper TJ, Hayward MW, Hartog M. Survey on the use of pulmonary scintigraphy and angiography for suspected pulmonary thromboembolism in the UK. *Clin Radiol* 1991;43:243–5.
- 64 Gottschalk A, Stein PD, Henry JW, Relyea B. Can pulmonary angiography be limited to the most suspicious side if the contralateral side appears normal on the ventilation/perfusion lung scan? Data from PIOPED Prospective Investigation of Pulmonary Embolic Diagnosis. *Chest* 1996;110:392–4.
- 65 Bernard SA, Jones BM, Stuckley JG. Pulmonary angiography in a non-teaching hospital over a 12-year period. *Med J Aust* 1992;157:589–92.
- 66 Hudson ER, Smith TP, McDermott VG, Newman GE, et al. Pulmonary angiography performed with iopamidol: complications in 1,434 patients. *Radiology* 1996;198:61–5.
- 67 Stein PD, Athanasoulis C, Alavi A, Greenspan RH, et al. Complications and validity of pulmonary angiography in acute pulmonary embolism. *Circulation* 1992;85:462–8.
- 68 van Beek EJ, Bakker AJ, Reekers JA. Pulmonary embolism: interobserver agreement in the interpretation of conventional angiography and DSA images in patients with nondiagnostic lung scan results. *Radiology* 1996;198:721–4.

Address for correspondence:

Dr P A Corris,
Regional Cardiothoracic Centre,
Freeman Hospital,
Newcastle upon Tyne NE7 7DW

Management of alcoholic hepatitis

Kevin Moore PhD FRCP, Centre for Hepatology, University College Medical School, London

Clin Med JRCPL 2001;1:281–4

It is estimated that there are 3,500–7,000 deaths per year from alcoholic hepatitis and/or cirrhosis in the UK^{1,2}. The incidence of cirrhosis in alcoholics at autopsy is about 10%. The average intake of alcohol in male and female alcoholics with cirrhosis is about 175 g/day and 120 g/day, respectively, for approximately eight years, although any alcohol consumption in excess of 60–80 g/day should cause concern. There is evidence of alcoholic hepatitis on liver biopsy in 30–60% of inpatients with alcoholic liver disease, and many patients presenting with alcoholic hepatitis have established cirrhosis at the time of diagnosis. However, the hepatic element is a clinically reversible entity.

Metabolism of alcohol

Alcohol is oxidised in the liver or stomach by alcohol dehydrogenase to acetaldehyde, which is then metabolised to acetate. It can be oxidised further through the citric acid cycle, or act as a precursor for the synthesis of fatty acids and fat. There are approximately 600 cal in a bottle of wine, one gram of alcohol providing about seven calories. Chronic alcohol abuse will result in induction of

the microsomal P450 ethanol oxidising system. P450 2E1 isoenzyme is the major P450 enzyme involved; it usually metabolises 10–15% of alcohol consumed. Microsomal oxidation of alcohol will generate reactive oxygen species or free radicals. These need to be inactivated or removed by a variety of scavenging or metabolising mechanisms such as catalase, glutathione peroxidase, vitamin C or vitamin E.

Pathogenesis

The pathogenesis of alcoholic liver disease involves the generation of reactive oxygen species which cause lipid peroxidation and secondary protein modification. Modified proteins may then act as foreign proteins and initiate an inflammatory response. Alcohol also increases the intestinal absorption of endotoxins and secondary activation of a variety of pro-inflammatory and pro-fibrotic cytokines. The combination of activated cytokines and altered cellular epitopes initiates hepatic inflammation and stellate cell activation. Malnutrition, causing depletion of cellular glutathione stores in alcoholics, aggravates this pro-inflammatory cascade (Fig 1).

Key Points

It is estimated that there are 3,500–7,000 deaths per year from alcoholic hepatitis and/or cirrhosis in the UK.

There is evidence of alcoholic hepatitis on liver biopsy in 30–60% of inpatients with alcoholic liver disease.

Many patients presenting with alcoholic hepatitis also have established cirrhosis at the time of diagnosis.

At the present time, there is no universally accepted treatment of alcoholic hepatitis, although good nutrition and a trial of steroids for one month is common.

Patients die usually from liver failure with a combination of hepatorenal syndrome, plus or minus variceal haemorrhage, plus or minus infections such as spontaneous bacterial peritonitis.

Pathology

The typical pathological features of alcoholic hepatitis are shown in Table 1.

Presentation of alcoholic liver disease

Patients with alcohol abuse may be asymptomatic but present with abnormal liver enzymes on routine blood tests and an enlarged liver. Clinically, they may be indistinguishable from patients with mild alcoholic hepatitis or even silent alcoholic cirrhosis. Cirrhosis frequently develops silently, and is manifest only when the patient develops hepatic decompensation with ascites or variceal haemorrhage.

Presentation of alcoholic hepatitis

Alcoholic hepatitis usually presents as an onset of malaise and jaundice, often with anorexia, nausea and vomiting. Patients have usually lost a considerable amount of weight and malnutrition is present in about 90%. There may be a dull ache over the liver. Many have stopped drinking recently, suggesting that a prodromal phase discourages further

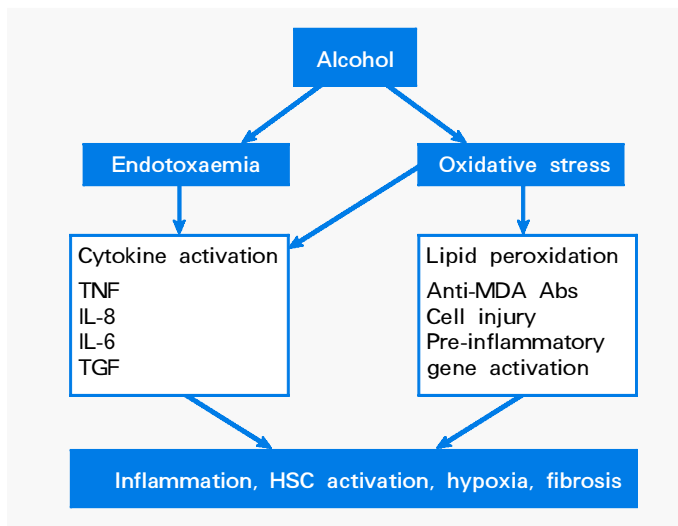


Fig 1. The pro-inflammatory cascade in alcoholic liver disease. Alcohol causes endotoxaemia, and oxidative stress, leading to cytokine activation and lipid peroxidation products which react with proteins to form covalently modified epitopes (eg reaction of malonaldehyde with a lysine residue to form a Schiff base). This, together with altered antioxidant status in the malnourished alcoholic patient, enhances the pro-inflammatory environment leading to hepatocyte necrosis, activation of hepatic stellate cells (HSC) and fibrosis (Abs = antibodies; IL = interleukin; MDA = malondialdehyde; TGF = transforming growth factor; TNF = tumour necrosis factor).

imbibing. Clinically, there are usually florid stigmata of chronic liver disease such as spider naevi and facial telangiectasia. Pyrexia is frequently present. Many patients develop ascites, but this may be absent even in severe cases. Acute

alcoholic hepatitis is often confused with viral hepatitis, but florid spider naevi, a very large liver, typical biochemistry (see below) and frequent leukocytosis are diagnostic markers of acute alcoholic hepatitis (Fig 2).

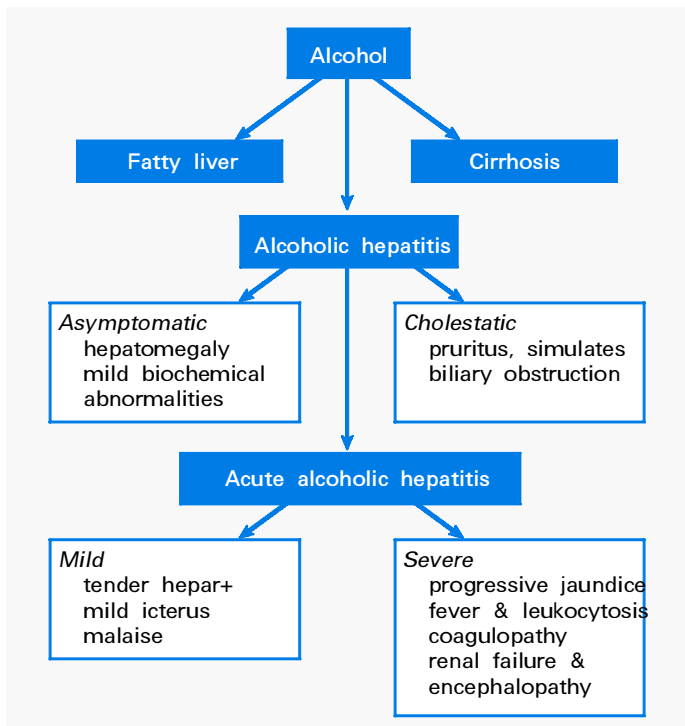


Fig 2. Underlying asymptomatic liver disease in patients with alcohol abuse. This may present with fatty liver, cirrhosis or acute alcoholic hepatitis. Alcoholic hepatitis may itself be asymptomatic or develop into a cholestatic syndrome. The presence of moderate or severe alcoholic hepatitis is serious as the associated mortality is high.

Table 1. Pathological features of alcoholic hepatitis.

Feature	
• Ballooning degeneration	All
• Fatty change	Usually present
• Inflammatory infiltrate (PMVs)	Always
• Fibrosis	Most
• Mallory's hyaline	75%

Despite use of the term 'alcoholic hepatitis', it is often not realised that alcoholic hepatitis is different biochemically from the situation in viral hepatitis. Thus, aspartate aminotransferase (AST) and alanine aminotransferase (ALT) are usually below 200 U/l, with AST higher than ALT. If transaminase activity exceeds this, alternative diagnoses should be considered. The characteristic biochemical and haematological features in a patient with alcoholic hepatitis are shown in Table 2. For example, a patient with alcoholic hepatitis might have a bilirubin level of 540 µmol/l, albumin 26 g/l, alkaline phosphatase 170 U/l, AST 78 U/l and ALT 35U/l.

Prognosis

The prognosis of alcoholic hepatitis is variable. The short-term mortality (<3 months) ranges from 15–55% for those with mild and severe alcoholic hepatitis, respectively^{3–8}. Severity is usually assessed by calculating the discriminant function (DF), as described by Maddrey and colleagues⁵, a DF score of over 32 indicating severe disease. In the UK,

mortality is currently 50% in patients with a DF above 32 (recent analysis of 241 patients from several centres: unpublished observation). DF is calculated as follows: $DF = (\text{bilirubin}/17) + (\text{prolongation of prothrombin time} \times 4.6)$. Thus, for a patient with a bilirubin level of 540 µmol/l, $DF = (540/17) + ((23-13) \times 4.6) = 20 + 46 = 66$.

Management of alcoholic hepatitis

General measures

The following should be undertaken in all patients:

- Admission to hospital unless the disease is mild and there is a good abstinent home environment.
- Screening for bacterial infections, including an ascitic fluid tap as appropriate, with a low threshold for starting antibiotics. Infections occur in 40% of those admitted with severe alcoholic hepatitis and cause 30% of all deaths⁹.
- Assessment of nutritional status by a dietitian and nutritional support given as necessary, including

nasogastric or intravenous feeding. A low protein diet should not be given even if severe hepatic encephalopathy is present. The current European Society for Parenteral and Enteral Nutrition (ESPEN) guidelines recommend that patients are given about 35 kcal/kg/day, 1.5 g/kg/day as protein¹⁰.

- Daily monitoring of liver and renal function until there is a consistent improvement of liver function tests (the incidence of development of the hepatorenal syndrome is high in those who continue to deteriorate).

Specific therapies

Steroids. At present, there is no universally accepted treatment of alcoholic hepatitis, although most liver centres currently ensure that patients receive good nutrition and are given a trial of steroids, usually prednisolone 40 mg/day for one month. The 14 published studies of steroid therapy for alcoholic hepatitis since 1971 have been subjected to a number of systematic reviews and meta-analyses⁸. Most of the clinical trials have found no overall benefit from steroid treatment, whereas some of the meta-analyses have found a slight benefit of steroid therapy^{11,12}.

The major problem with the meta-analyses has been the grouping together of a heterogeneous group of trial protocols. This includes the most recent, and currently widely quoted, meta-analysis which found no benefit for steroids. Although there was a trend of benefit with steroids, the results were not statistically significant ($p = 0.2$) despite the publication bias favouring steroid treatment⁸. The most recent and successful steroid trial has been the subject of two reports^{4,13}. Overall survival at six months in the groups treated with steroids was 73% and 84%, compared with 41% in the placebo group ($p = 0.02$). However, by two years the mortality in all three groups was identical. Thus, in this study, prednisolone was associated with a short-term improvement in mortality in patients with histologically proven severe alcoholic hepatitis (DF >32).

Table 2. Typical biochemical and haematological findings in alcoholic hepatitis.

Main features	
Bilirubin	High (variable: 50–1,000 µmol/l)
Albumin	Low
Alkaline phosphatase	Slightly elevated
AST	<200 U/l (may be just above upper limit of normal)
ALT	<200 U/l (may be normal)
Other features	
Sodium	Low
Potassium	Low (potassium depletion)
Urea	Low unless HRS present
Creatinine	Variable, depending on renal function
Ferritin	Very high (often >1,000 µg/l, acute phase protein)
IgA	Markedly increased
Zinc	Low
Haemoglobin	Low
Leukocytosis	Often 12–20 x 10 ⁹ /l
MCV	High
Platelets	Low (alcohol effect and hypersplenism for portal hypertension)
Prothrombin time	Often prolonged (suggests cirrhosis)
Cholestasis	Cholestatic liver function tests are occasionally seen

ALT = alanine aminotransferase; AST = aspartate aminotransferase; HRS = hepatorenal syndrome; IG = immunoglobulin; MCV = mean corpuscular volume.

The largest study (263 patients), which also included patients with moderate alcoholic hepatitis, evaluated three treatments (steroids, placebo and oxandrolone) and found no survival benefit on steroids. Indeed, the mortality at two months in the group with severe alcoholic hepatitis given steroids (48%) was not significantly different from those given placebo (33%)³. At one year the cumulative mortality in the two groups was 62% (placebo) and 58% (steroids).

Thus, although the use of steroids in alcoholic hepatitis is to some extent still contentious, and further studies are required, at present the mainstay of treatment is abstinence, nutritional support and short-term steroid therapy.

Other treatments. A variety of other treatments has been tried in alcoholic hepatitis (Table 3). Some may have shown improvements, but the absence of further studies and the abandonment of their use suggests that they are ineffective.

Complications of alcoholic hepatitis

Alcoholic hepatitis may follow an inexorably progressive course, with progressive jaundice and liver failure. Patients die usually from liver failure with a combination of hepatorenal syndrome plus or minus variceal haemorrhage, plus or minus infections such as spontaneous bacterial peritonitis. Most patients develop hepatic encephalopathy with progressive disease. The development of hepatorenal syndrome carries a high mortality. Apart from measures to improve renal function such as fluid support, pressor support (eg glypressin)¹⁴ with or without N-acetylcysteine¹⁵, renal support with haemodialysis or haemo-

Table 3. Treatments that have been tried in alcoholic hepatitis.

- Steroids
- Propylthiouracil
- Insulin & glucagon
- Amlodipine
- Parenteral nutrition
- Androgenic steroids
- Colchicine
- Amino acid infusion

filtration should be considered. The survival of patients with alcoholic hepatitis undergoing dialysis is about 12%. Although these survival figures are poor, in this author's view renal support should be given to most patients with alcoholic hepatitis and hepatorenal syndrome if other organs are functioning well. For those requiring ventilation, the mortality is very high and dialysis probably just prolongs dying.

References

- 1 Saunders J, Latt N. Epidemiology of alcoholic liver disease. *Baillière's Clin Gastroenterol* 1993;7:55–584.
- 2 Anderson P. Excess mortality associated with alcohol consumption. *Br Med J* 1988; 297:824–6.
- 3 Mendenhall CL, Anderson S, Garcia-Pont P, Goldberg S, et al. Short-term and long-term survival in patients with alcoholic hepatitis treated with oxandrolone and prednisolone. *N Engl J Med* 1984;311:1464–70.
- 4 Ramond MJ, Poynard T, Rueff B, Mathurin P, et al. A randomised trial of prednisolone in patients with severe alcoholic hepatitis. *N Engl J Med* 1992;326:507–12.
- 5 Maddrey WC, Boitnott JK, Bedine MS, Weber FL Jr, et al. Corticosteroid therapy of alcoholic hepatitis. *Gastroenterology* 1978;75:193–9.
- 6 Carithers RL Jr, Herlong HF, Diehl AM, Shaw EW, et al. Methylprednisolone

therapy in patients with severe alcoholic hepatitis. A randomized multicenter trial. *Ann Intern Med* 1989;110:685–90.

- 7 Sheron N, Bird G, Koskinas G, Portmann B, et al. Circulating and tissue levels of the neutrophil chemotaxin interleukin-8 are elevated in severe acute alcoholic hepatitis, and tissue levels correlate with neutrophil infiltration. *Hepatology* 1993;18:41–6.
- 8 Christensen E, Gluud C. Glucocorticoids are ineffective in alcoholic hepatitis: a meta-analysis adjusting for confounding variables. *Gut* 1995;37:113–8.
- 9 Cabre E, Rodriguez-Iglesias P, Caballeria J, Quer JC, et al. Short- and long-term outcome of severe alcohol-induced hepatitis treated with steroids or enteral nutrition: a multicenter randomized trial. *Hepatology* 2000;32:36–42.
- 10 Plauth M, Merli M, Weimann A, Ferenci P, Muller MJ. ESPEN guidelines for nutrition in liver disease and transplantation. *Clin Nutr* 1997;16:43–55.
- 11 Imperiale TF, McCullough AJ. Do corticosteroids reduce mortality from alcoholic hepatitis? A meta-analysis of the randomized trials. *Ann Intern Med* 1990;113: 299–307.
- 12 Poynard T, Ramond MJ, Rueff B, Mathurin P, et al. Corticosteroids reduce mortality from alcoholic hepatitis in patients without encephalopathy. A meta-analysis of randomized trials (RCTs) including French trials. *Hepatology* 1991;14:234A.
- 13 Mathurin P, Duchatelle V, Ramond M J, Degott C, et al. Survival and prognostic factors in patients with severe alcoholic hepatitis treated with prednisolone. *Gastroenterology* 1996;110:1847–53.
- 14 Dagher L, Patch D, Marley R, Moore K, Burroughs A. Review article: pharmacological treatment of the hepatorenal syndrome in cirrhotic patients. *Aliment Pharmacol Ther* 2000;14:515–21.
- 15 Holt S, Goodier D, Marley R, Patch D, et al. Improvement in renal function in hepatorenal syndrome with N-acetylcysteine. *Lancet* 1999;353:294–5.

Address for correspondence:

Dr Kevin Moore, Centre for Hepatology, Royal Free Campus, University College Medical School, London NW3 2QG