Clinical Medicine 2010, Vol 10, No 2: 194–5

lesson of the month (1)

FAST positive does not always mean stroke

Patients who are face, arm, speech test (FAST) positive may have a stroke mimic diagnosis. Careful attention to the speed of onset of symptoms is paramount. Magnetic resonance imaging is helpful in supplementing the clinical assessment.

Lesson

A 58-year-old, right-handed man presented to the transient ischaemic attack (TIA) clinic after waking with right-sided weakness and speech disturbance two weeks previously. He was a smoker with a history of hypercholesterolaemia. Clinical examination revealed normal blood pressure, mild expressive dysphasia and pyramidal weakness on the right with mild pronator drift, increased tone, brisk reflexes and a right extensor plantar response.

Routine blood tests, electrocardiogram (ECG) and carotid Doppler ultrasound were normal. Serum cholesterol was 6.2 mmol/l. A computed tomography (CT) brain scan showed low density within the left corona radiata consistent with a recent stroke (Fig 1a). The patient was started on aspirin and simvastatin. However, his symptoms had fluctuated since onset so magnetic resonance imaging (MRI) was performed and showed a rounded left periventricular lesion with peripheral enhancement (Figs 1b and 1c), suspicious of demyelination. Diffusion-weighted imaging (DWI) showed restricted diffusion (Fig 1d) and fluid attenuated inversion recovery images showed increased signal intensity in this lesion (Fig 1e), findings suggestive, but not diagnostic, of demyelination. Lumbar puncture showed faint oligoclonal bands unmatched to the serum. The clinical diagnosis was type 3 clinically isolated syndrome (CIS). The patient was given intravenous methylprednisolone 1 g daily for three days. Follow-up MRI showed significant improvement in the periventricular lesion (Fig 1f) correlating with good clinical recovery.

Comment

The treatment of stroke in the UK is becoming increasingly active.[1] The UK National Stroke Strategy promotes rapid assessment and treatment of patients with stroke-like symptoms.[2] Ambulance staff using the face, arm, speech test (FAST) correctly diagnose 80% of stroke patients.[3,4] Acute physicians may assume a working diagnosis of stroke and subsequent thinking may be influenced by this, including the interpretation of neuroimaging tests.

However, ECASS II reported 17% of patients thrombolysed were subsequently thought not to have had a stroke.[5] It may be difficult to distinguish stroke from other mimicking conditions such as multiple sclerosis (MS), tumours, postictal paresis, hemiplegic migraine and hypoglycaemia.[6] Equally, vascular syndromes, such as cerebral autosomal dominant arteriopathy with subcortical infarcts and leukoencephalopathy, can be misdiagnosed as MS.[7]

In acute stroke, CT has 60% sensitivity versus 91% for DWI.[8] MRI has a sensitivity of about 80% for acute stroke and this is increased to over 90% with the addition of DWI.[9] Interrater reliability is higher for DWI than for CT in detecting acute ischaemic stroke.[10] MRI is much better than CT at differentiating between demyelination and ischaemia. The addition of perfusion MRI may also be of use; mean transit time (MTT) is increased in acute ischaemic stroke compared to acute demyelination.[11] However, DWI and apparent diffusion coefficient may be abnormal in both demyelination and ischaemia.

Careful assessment of the onset of symptoms in cases of suspected stroke and particular awareness of stroke mimics in cases discovered on waking from sleep is advised. The temporal course of symptoms is crucial in differentiating demyelination and stroke. Brain imaging is still unable to conclusively differentiate both diagnoses in all cases so clinical acumen remains paramount in the assessment of acute stroke symptoms.

As acute treatment of stroke becomes faster in the UK, it is important to remain vigilant for stroke mimics.

Barry Moynihan,[1] consultant in stroke medicine; **Rumana Chowdhury,**[2] specialist registrar in neurology; **Anthony Pereira,**[1] consultant neurologist

[1]Department of Neurology, St George's Hospital, London
[2]St Thomas' Hospital, London

References

1 Markus H. Improving the outcome of stroke. *BMJ* 2007;335:359–60.
2 Department of Health. *National Stroke Strategy*. London: DH, 2007.
3 Harbison J, Hossain O, Jenkinson D *et al.* Diagnostic accuracy of stroke referrals from primary care, emergency room physicians, and ambulance staff using the face arm speech test. *Stroke* 2003;34:71–6.
4 Nor AM, McAllister C, Louw SJ *et al.* Agreement between ambulance paramedic- and physician-recorded neurological signs with Face Arm Speech Test (FAST) in acute stroke patients. *Stroke* 2004;35:1355–9.
5 Hacke W, Kaste M, Fieschi C *et al.* Randomised double-blind placebo-controlled trial of thrombolytic therapy with intravenous alteplase in acute ischaemic stroke (ECASS II). Second European-Australasian Acute Stroke Study Investigators. *Lancet* 1998;352:1245–51.
6 Hand PJ, Kwan J, Lindley RI, Dennis MS, Wardlaw JM. Distinguishing between stroke and mimic at the bedside: the brain attack study. *Stroke* 2006;37:769–75.
7 O'Riordan S, Nor AM, Hutchinson M. CADASIL imitating multiple sclerosis: the importance of MRI markers. *Mult Scler* 2002;8:430–2.

© Royal College of Physicians, 2010. All rights reserved.

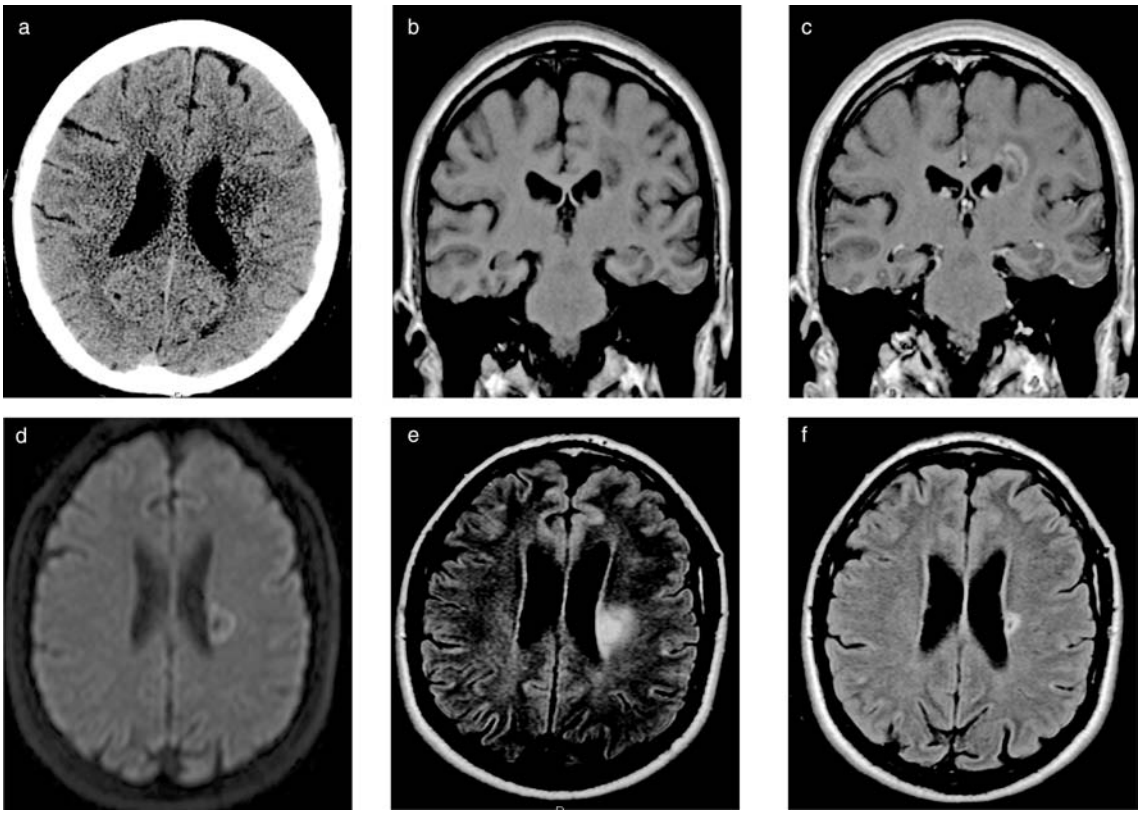

Fig 1. A 58-year-old male awoke with a right hemiparesis and dysphasia. a) Non-contrast computed tomography brain scan showing an area of hypodensity in the left corona radiata. b) T1-weighted magnetic resonance imaging (MRI) performed two weeks later showing hypointensity in the left periventricular region. c) Contrast-enhanced T1-weighted MRI showing peripheral enhancement in this lesion. d) Diffusion-weighted imaging showing restricted diffusion in the periventricular lesion suggestive of ischaemia or demyelination. e, f) Fluid attenuated inversion recovery images showing sequential attenuation of the periventricular lesion at zero and six months following treatment with intravenous methylprednisolone.

8 Fiebach JB, Schellinger PD, Jansen O *et al.* CT and diffusion-weighted MR imaging in randomized order: diffusion-weighted imaging results in higher accuracy and lower interrater variability in the diagnosis of hyperacute ischemic stroke. *Stroke* 2002;33:2206–10.
9 Lansberg MG, Norbash AM, Marks MP *et al.* Advantages of adding diffusion-weighted magnetic resonance imaging to conventional magnetic resonance imaging for evaluating acute stroke. *Arch Neurol* 2000;57:1311–6.
10 Saur D, Kucinski T, Grzyska U *et al.* Sensitivity and interrater agreement of CT and diffusion-weighted MR imaging in hyperacute stroke. *Am J Neuroradiol* 2003;24:878–85.
11 Zivadinov R, Bergsland N, Stosic M *et al.* Use of perfusion- and diffusion-weighted imaging in differential diagnosis of acute and chronic ischemic stroke and multiple sclerosis. *Neurol Res* 2008;30:816–26.

Address for correspondence: Dr A Pereira, Department of Neurology, St George's Hospital, Tooting, London SW17 0QT.
Email: Anthony.pereira@stgeorges.nhs.uk

© Royal College of Physicians, 2010. All rights reserved.