

Table 1. Strategy to try to improve all aspects of selection process for insertion of the percutaneous endoscopic gastrostomy (PEG) tube.

Standardise PEG referral form including concomitant disease
Endoscopy nurse triage and dissemination of published evidence
Gastroenterological review where necessary
Holistic and multidisciplinary approach
Advise against PEG feeding in patients with dementia
One-week waiting list policy

recent report, allows clinicians to have an evidence-based discussion about feeding with all interested parties. It also allows clinicians within the UK to have local, or at least UK, data, which are possibly relevant to their own practice. Perhaps this is a practical solution to a highly emotive problem?⁴

MATTHEW KURIEN

Specialty registrar in gastroenterology

DAVID S SANDERS

*Consultant gastroenterologist
and honorary professor in gastroenterology*

*Department of Gastroenterology
Royal Hallamshire Hospital, Sheffield*

References

- Mitchell SL, Teno JM, Kiely DK *et al.* The clinical course of advanced dementia. *N Engl J Med* 2009;361:1529–38.
- Sanders DS, Carter MJ, D'Silva J *et al.* Survival analysis in percutaneous endoscopic gastrostomy: a worse outcome in patients with dementia. *Am J Gastroenterol* 2000;95:1472–5.
- Sanders DS, Carter MJ, D'Silva J *et al.* Percutaneous endoscopic gastrostomy: a prospective audit of the impact of guidelines in 2 district general hospitals in the United Kingdom. *Am J Gastroenterol* 2002;97:2239–45.
- Sanders DS, Anderson AJ, Bardhan KD. Percutaneous endoscopic gastrostomy: an effective strategy for gastrostomy feeding in patients with dementia. *Clin Med* 2004;4:235–41.

Do medical patients know the name of their consultant?

Editor – We are writing in response to the letter by Pittman and colleagues in the December 2009 issue of *Clinical Medicine*

and their survey on whether patients know the name of their consultant (*Clin Med* December 2009 pp 633–4).

We are in agreement that this is an important issue. Not knowing who is in charge of your care can add to the bewilderment and anxiety surrounding a hospital admission. One solution, developed by our firm, is for the consultant to give every patient on the post-take ward round a business card with his name and contact details (including email address) (Fig 1). The card is larger than normal (12.5 cm by 7.5 cm) and we use a bigger font size (14 point) to assist the visually impaired.

We feel that this approach demonstrates strong leadership by ensuring that the patient and family are clear as to who is in charge of their care. In our experience we have found this strategy to be well received by patients and families.

DHANUPRIYA SIVAPATHASUNTHARAM

Specialist registrar

VICTORIA REAY

Core medical trainee

MARK KINIRONS

Consultant physician

Guys and St Thomas' NHS Trust, London

The skin in general medicine

Editor – Dhoat and Rustin reviewed an important but often neglected part of general medicine in their article (*Clin Med* August 2009 pp 379–84). We would like to add that xanthomatoses, especially xanthelasmas, are also an important marker for diabetes, propensity to coronary artery disease (CAD)¹ and gout² apart from cholestasis and hyperlipidemia as mentioned. Besides xanthelasma and xanthoma, presence of arcus juvenilis in young people (age ≤ 40 years) may also be considered as a clinical sign for premature CAD.³ Premature graying and/or balding in chronic smokers has also been shown to be associated with premature CAD.⁴ Other cutaneous signs like ear lobe crease, ear canal hair, and nicotine staining should

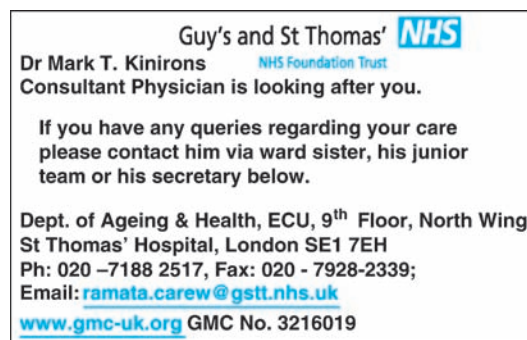


Fig 1. An example of the business card.

also be considered as valuable clinical markers of CAD.¹ Recently, hyperpigmented palm and digits of hand associated with central obesity in betel quid sellers has been shown to predispose to early CAD.⁵ There may be a clinical scenario where one sibling in the family has xanthoma, another has xanthelasma or arcus juvenilis and some suffer from CAD. The clinical implication of such a finding is that one must actively look for such signs in all family members for early identification of persons predisposed to premature CAD.

SHRIDHAR DWIVEDI

Professor of medicine/preventive cardiology

AMITESH AGGARWAL

Lecturer

*University College of Medical Sciences
University of Delhi, India*

References

- Chan HL. Cutaneous manifestations of cardiac diseases. *Singapore Med J* 1990;31:480–5.
- Storey GO. Xanthomatosis, hyperlipoproteinaemia (type II, Fredrickson), gout, cardiac infarction. *Proc R Soc Med* 1971;64:59–60.
- Chambless LE, Fuchs FD, Linn S *et al.* The association of corneal arcus with coronary heart disease and cardiovascular disease mortality in the Lipid Research Clinics Mortality Follow-up Study. *Am J Public Health* 1990;80:1200–4.
- Dwivedi S, Aggarwal A. Risk factors and cutaneous markers of coronary artery disease in young in north Indian population. *Atherosclerosis Supplement* 2009;10:e1406.
- Dwivedi S, Dwivedi G. Betel quid seller syndrome. *Occup Environ J* 2010;67:144.