Clinical Medicine 2010, Vol 10, No 4: 379–80

A 66-year-old woman with recurrent pulmonary oedema

Matt P Wise, Elize Richards and Graham Walker

Case presentation

A 66-year-old woman presented to the emergency department with increasing dyspnoea and chest pain. According to the attending relatives the patient had only been able to climb five steps during the previous 12 months and had recently become housebound due to deteriorating breathlessness. A partial thyroidectomy performed 30 years earlier for a right-sided adenoma, had reoccurred two decades later. The patient smoked 50 packs of cigarettes a year and had been on bronchodilators for several years following a diagnosis of chronic obstructive pulmonary disease (COPD) but found these medicines ineffective. On presentation the patient was moribund. Pupils were equal and reacted to light. Respiratory rate was recorded at 35 breaths per minute with oxygen saturations of 68% on high flow oxygen. Inspiratory crackles were present throughout both lungs on auscultation. The patient had a sinus tachycardia and hypotension with a blood pressure of 60/30 mmHg. Abdominal examination was unremarkable. A smooth, largely right-sided, goitre was noted on general examination. Left bundle branch block was present on an electrocardiogram (ECG) and a chest X-ray demonstrated pulmonary oedema (Fig 1). Arterial blood gas analysis, taken on high flow oxygen, were as follows: pH 6.9, PaO_2 7.7 kPa, $PaCO_2$ 14.1 kPa, lactate 10.3 mmol/l, BE −10.3 mmol/l and HCO_3^- 12.8 mmol/l.

What is the differential diagnosis and the most likely diagnosis?

Differential diagnosis includes pulmonary oedema, pneumonia with septic shock, exacerbation of COPD or pulmonary embolus with pulmonary aspiration and intracerebral event with neurogenic pulmonary oedema. The history of chest pain in a smoker with clinical and radiological findings of pulmonary oedema and left bundle branch block suggest a diagnosis of pulmonary oedema due to myocardial infarction in a patient with severe COPD. The findings could also be explained by a pulmonary embolus or exacerbation of COPD causing loss of consciousness followed by pulmonary aspiration. Unremarkable inflammatory markers and temperature were inconsistent with a diagnosis of pneumonia and septic shock. The history of progressive dyspnoea, chest pain and equal pupils reactive to light did not support a diagnosis of an intracerebral catastrophe with neurogenic pulmonary oedema.

Matt P Wise, consultant critical care, Adult Critical Care, University Hospital of Wales, Cardiff; **Elize Richards,** consultant anaesthetist, Department of Anaesthetics, Horton Hospital, Banbury; **Graham Walker,** consultant anaesthetist, Department of Anaesthetics, Horton Hospital, Banbury

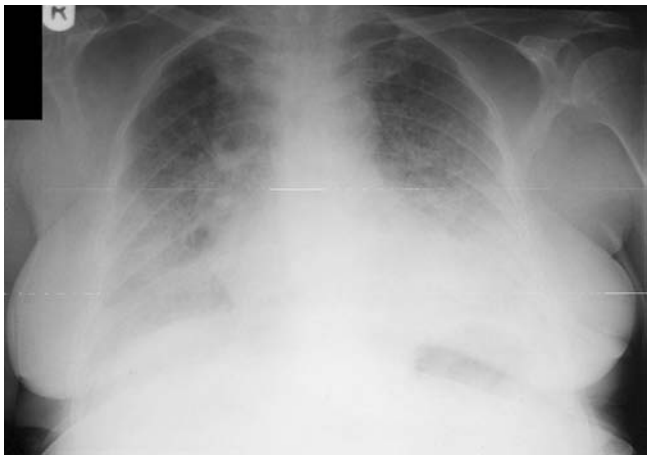

Fig 1. Erect antero-posterior film taken on admission showing pulmonary oedema.

What is the initial management?

The patient was shocked, in respiratory failure and moribund. Initial management mandates intubation and mechanical ventilation in the emergency department, which resulted in an immediate improvement in oxygenation. The patient was administered thrombolysis, diuretic, aspirin and ventilated in the intensive care unit. There was a rapid improvement in haemodynamics, acidosis and oxygenation. The bundle branch block resolved, there was a small rise in troponin I of 3.2 mcg/l (<1.0) with a normal creatinine kinase of 93 IU/l (24–170). Routine blood tests including thyroid function were unremarkable. The initial prognosis was thought to be poor as the patient was housebound with COPD and had presented with pulmonary oedema. An ECG was organised to document myocardial function.

Case progression

The following day the patient was extubated but 14 hours later became hypoxic and tachycardic with recurrence of left bundle branch block. Following reintubation the abnormal physiology again rapidly resolved. An echocardiogram showed good left ventricular function with an ejection fraction >60%. The patient was extubated for a second time with a similar pattern of events as previously, but on this occasion respiratory distress occurred within 15 minutes and stridor was noted. The recurrence of pulmonary oedema, which rapidly resolved with intubation in a patient with goitre, prompted a computerised tomography (CT) scan of the neck and chest (Fig 2). The CT demonstrated a predominantly right-sided goitre extending into the superior mediastinum and abutting the trachea (splinted by

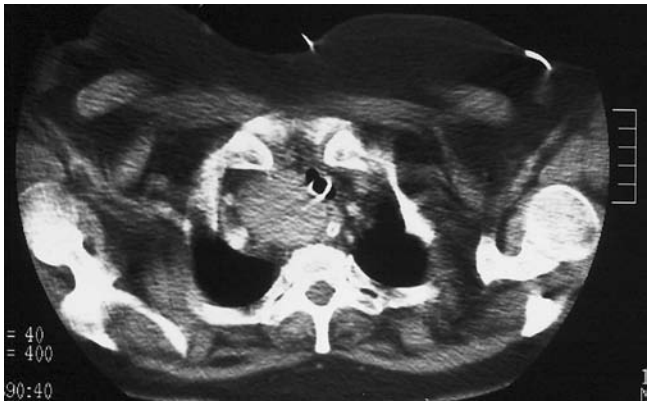

Fig 2. Computed tomography scan of chest at thoracic inlet showing an enlarged right thyroid lobe compressing the trachea, which is splinted by the endotracheal tube.

Key learning points

- Negative pressure pulmonary oedema is an uncommon but easily treatable cause of non-cardiogenic pulmonary oedema caused by respiratory efforts against an obstructed airway. Relief of airway obstruction, oxygen and positive pressure ventilation usually lead to a rapid resolution of pulmonary oedema often without diuretic treatment.
- Although negative pressure pulmonary oedema is recognised in anaesthetic practice as an accepted complication of laryngeal extubation it can be easily overlooked in the emergency department or intensive care unit unless specifically considered in the differential diagnosis of pulmonary oedema.
- Pulmonary function tests including a flow volume loop can distinguish different causes of airway obstruction. In this case it would have established that the patient had extrinsic airway compression rather than COPD as the cause of dyspnoea.
- Airway obstruction is common in thyroid disease and needs to be considered, as many patients are asymptomatic.

the endotracheal tube). The unifying diagnosis is therefore negative pressure pulmonary oedema caused by thyroid enlargement compressing the trachea. A right thyroid lobectomy was performed for multinodular goitre and the endotracheal tube was removed four hours after surgery. The patient was discharged home after two days and was no longer breathless on exertion with normal exercise capacity.

Discussion

Negative pressure pulmonary oedema or postobstructive pulmonary oedema is an uncommon but well documented complication following removal of an endotracheal tube, usually precipitated by laryngospasm.[1] In one large retrospective series it occurred with an incidence of 0.094% of surgical patients, mostly among healthy middle-aged males.[2] Although negative pressure pulmonary oedema is easily recognised in anaesthetic practice it is much rarer to observe this phenomenon in either the emergency department or intensive care unit where the correct aetiology is more likely to be overlooked.[3] It may occur in other causes of upper airway obstruction including biting the endotracheal tube or laryngeal mask, epiglottitis, tumour, foreign body, hanging, tracheomalacia and goitre. Oedema develops when inspiratory efforts are made against an occluded airway leading to large negative intrathoracic pressures.

Oedema occurs as a consequence of altered hydrostatic forces.[4] Extremely large negative intrathoracic pressures can be generated against an obstructed airway increasing venous return and pulmonary venous pressure. Simultaneously the negative intrathoracic pressure and hypoxia depress cardiac output and increase systemic vascular resistance with a consequent rise in pulmonary venous pressure, again favouring the formation of alveolar oedema through a hydrostatic mechanism.[4] Generally negative pressure pulmonary oedema responds to simple measures such as oxygen, relief of the obstruction and positive pressure ventilation, often without the need for diuretics. Although negative pressure pulmonary oedema may occur with some delay in patients at risk, a period of 14 hours after extubation is unusual, and probably reflects that laryngospasm is the cause in the majority of described cases rather than extrinsic airway compression.

Tracheal compression is described in as many as a third of patients referred to thyroid clinics, but surprisingly little correlation exists between symptoms predictive of upper airway obstruction and the presence of an abnormal flow volume loop.[5] In patients in whom airway obstruction is detected, as many as 42% are asymptomatic and 72% are not breathless. A flow volume loop is essential in assessing airway obstruction in these individuals, as symptoms and clinical examination are poor correlates. The patient described here had been breathless for a prolonged period of time and her symptoms were erroneously ascribed to COPD because of an extensive smoking history. On admission to hospital the patient was moribund with profound hypoxia, hypotension and acidosis. In this context the cardiovascular changes were mistakenly thought to reflect an acute coronary syndrome in a patient with severely limiting COPD. This demonstrates the importance of performing spirometry including a flow volume loop when investigating breathless patients, not only for the diagnosis of COPD (and subsequent management), but for excluding other causes of dyspnoea.

References

1 Hartley M, Vaughan RS. Problems associated with tracheal extubation. *Br J Anaesth* 1993;71:561–8.
2 Deepika K, Kenaan CA, Barrocas AM, Fonseca JJ, Bikazi GB. Negative pressure pulmonary oedema after acute upper airway obstruction. *J Clin Anesth* 1997;9:403–8.
3 Koh MS, Hsu AA, Eng P. Negative pressure pulmonary oedema in the medical intensive care unit. *Intensive Care Med* 2003;29:1601–4.
4 Fremont RD, Kallet RH, Matthay MA, Ware LB. Postobstructive pulmonary edema: a case for hydrostatic mechanisms. *Chest* 2007;131:1742–6.
5 Gittoes NJ, Miller MR, Daykin J, Sheppard MC, Franklyn JA. Upper airways obstruction in 153 consecutive patients presenting with thyroid enlargement. *BMJ* 1996;312:484.

Address for correspondence: Dr MP Wise, Adult Critical Care, University Hospital of Wales, Heath Park, Cardiff CF14 4XW. Email: mattwise@doctors.org.uk