

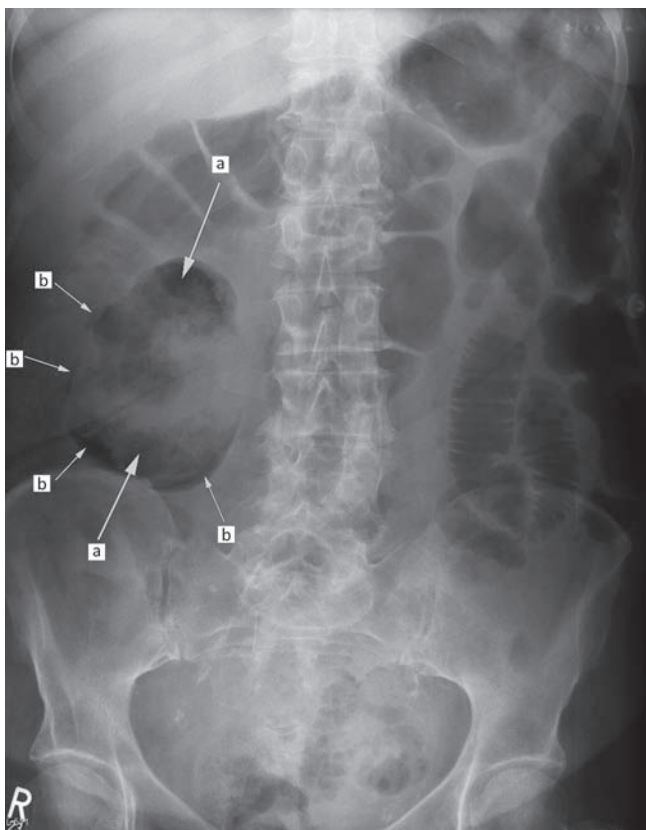
# Emphysematous pyelonephritis

Edward Sellon, Neil Sharma, Nick Taylor, Neil Barlow and David Howlett

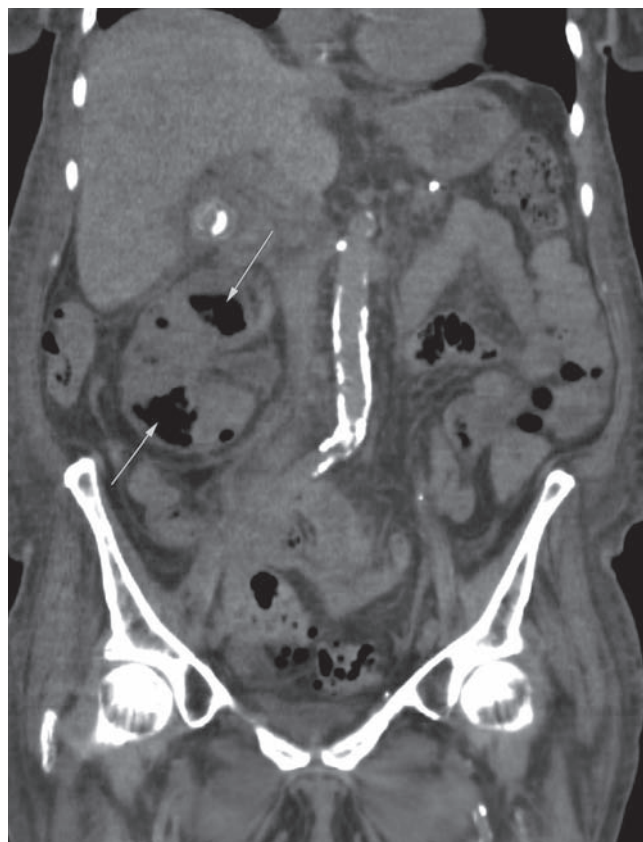An 82-year-old diabetic lady presented with acute confusion. She was afebrile, hyperglycaemic and in acute renal failure. Her abdomen was mildly distended and she had loin tenderness. An abdominal radiograph shows extensive gas within the right renal parenchyma and subcapsular region (Fig 1). These findings were confirmed with a CT scan (Fig 2). Findings are consistent with those of emphysematous pyelonephritis, to which diabetics are prone. There is no gas extension into the ureter, bladder or retroperitoneum. Initial symptoms and signs are often non-specific and there is a high associated mortality

unless treated aggressively. Treatment revolves around fluid resuscitation and systemic antibiotics for *E. coli* and *Klebsiella* species. Percutaneous drainage is indicated in cases with obstruction.

**Address for correspondence:** Major E Sellon, Department of Radiology, Eastbourne District General Hospital, Kings Drive, Eastbourne, East Sussex BN21 2UD.  
**Email:** edwardsellon@hotmail.com



**Fig 1.** An abdominal radiograph showing extensive gas within the right renal parenchyma (a) and subcapsular region (b).



**Fig 2.** CT scan with unenhanced coronal section images with arrows showing intra-substance gas within the right kidney.

Edward Sellon, SpR radiology; Neil Sharma, consultant physician; Nick Taylor, medical illustrator; Neil Barlow, consultant radiologist; David Howlett, consultant radiologist

Eastbourne District General Hospital, East Sussex, UK