*Clinical Medicine* 2013, Vol 13, No 4: 353–7

# Evidence underlying the clinical management of diabetic macular oedema

Michael Andrew Williams and Usha Chakravarthy

**ABSTRACT – Diabetic retinopathy (DR) is the leading cause of visual loss in the developed world in those of working age, and its prevalence is predicted to double by 2025. The management of diabetic retinopathy has traditionally relied on screening, on laser treatment delivered by ophthalmologists, and on optimising blood glucose and blood pressure. Recent evidence suggests that the role of systemic factors is more complex than originally thought, and that drugs such as ACE inhibitors, fibrates and glitazones may all influence the course of diabetic macular oedema. Antagonism of vascular endothelial growth factor offers a new therapeutic avenue that may transform the management of diabetic macular oedema. Several other therapeutic options are under investigation and development, including aminoguanidine, sorbinol, ruboxistaurin and autologous stem cell transfusion.**

**KEY WORDS: Retinopathy, diabetes, macular**

## Definitions and diagnosis

Diabetic macular oedema (DMO) (Fig 1) is a component of the clinical scenario that comprises diabetic retinopathy (DR). DMO consists of intraretinal fluid and exudate gathering at or close to the central region of the retina, the macula; this is the region serving central vision and thus DMO can impair central vision. Proliferative retinopathy, in which new blood vessels develop on the retinal surface at the optic disc, or elsewhere, also forms part of DR. These new blood vessels can bleed, causing vitreous haemorrhage, or contract, resulting in retinal detachment. DR is diagnosed by clinical examination (fundoscopy), though screening plays a vital role as patients with DMO or proliferative DR will not necessarily have symptoms initially. Optical coherence tomography scans (OCT) offer a new way to monitor macular anatomy quantitatively, and are used to guide clinical practice and as an outcome measure in clinical trials.[1] This review gives an overview of DMO management, and puts systemic factors in context.

## Epidemiology

Diabetic retinopathy is a leading cause of visual loss in 20- to 65-year-olds in the developed world.[2] The prevalence of DR increases with duration of DM, with increased HbA1c and with higher blood pressure (BP) and is higher in type 1 than in type 2 DM.[2] Approximately 8% of those with DM have DMO in at least one eye, and one in four patients with DMO has significant visual impairment,[3] though estimates of prevalence and rate of progression of DR vary with study methodology and population sampled, for example with regard to ethnicity.[2]

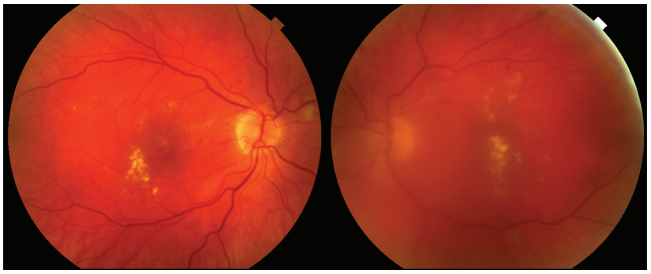

**Fig 1. Bilateral diabetic macular exudates.** The view of the left fundus is blurred due to cataract.

## Pathophysiology

Why the macula is predisposed to oedema in DR is not established.[4] The retina is uniquely susceptible to ischaemia, as it is the most metabolically active tissue in the body supplied by an end-arterial system with little spare capacity. It is speculated that structural and functional changes in DM in the retina also occur in other microvascular beds. Modification of lipoproteins may be central to damage of the retinal milieu in DM.[5] Apoptosis of neural cells also occurs at an increased rate soon after the onset of DM in animal models.[6]

## Screening

The NHS Diabetic Eye Screening Programme quality assurance standards state that every eligible person with DM over the age of 12 years in the UK should be invited for DR screening test at least once a year. The screening programme relies on retinal photographs, which are analysed to identify high risk features that merit onward referral to the hospital eye service. Early detection and treatment of diabetic eye disease has been shown to improve outcomes.[7] While approximately 10% of patients with type 2 DM have signs of retinopathy at the time of diagnosis, it is likely that molecular manifestations of the disease precede clinical signs by years.

**Michael Andrew Williams**,[1] specialist registrar in medical ophthalmology; **Usha Chakravarthy**,[2] clinical professor

[1]Belfast Health and Social Care Trust; [2]Centre for Vision and Vascular Science, Queen's University of Belfast

At present, however, screening relies on detection of haemorrhages, exudates or other signs. The uptake of screening in the UK is estimated by Diabetes UK to be approximately 90%. Pregnant women are at greater risk of DR progression and should be examined more frequently.[8]

## New insights on how diabetic retinopathy is influenced by systemic risk factors

The UK Prospective Diabetes Study (UKPDS)[9,10] and the Diabetes Control and Complications Trial (DCCT)[11] established the benefit of intensive glycaemic and blood pressure control in delaying the onset and slowing the progression of DR.

The benefits of ever tighter glycaemic and BP control for retinopathy progression were not questioned until recently. The Action to Control Cardiovascular Risk in Diabetes (ACCORD) trial[12] was stopped six months early as intensive glycaemic control was associated with increased mortality, mainly from macrovascular causes. This was unexpected and, as yet, is unexplained. It was suggested that less strict glycaemic targets may be appropriate in elderly patients with established cardiovascular disease. The role of gylcaemic control is not simple: long-term follow-up of participants enrolled in clinical studies on DM years ago have led to the concept of a 'metabolic memory' or 'legacy effect', whereby a period of better glycaemic control early in the disease course can have lasting benefits despite subsequent poorer control.[13] Furthermore, in ACCORD, keeping the systolic BP below 120 mmHg did not slow retinopathy progression. This was thought to be due to a floor effect as the control group had a mean systolic BP of 133 mmHg. Clearly a compromise must be struck between adequately and excessively lowering BP levels, bearing in mind the benefit of lower BP on other endpoints such as nephropathy and stroke.

The Collaborative Diabetes Atorvastatin Study (CARDS) was a primary prevention trial on DR[14] in which almost 3,000 participants with type 2 DM were randomised to receive atorvastatin or placebo. There was a trend towards reduction in the need for laser therapy with atorvastatin, though this was not statistically significant. In the STENO-2 trial, 160 subjects were randomised either to intensive control of blood glucose, BP and lipids, or to 'conventional' treatment. [15] The relative risk after a mean of 5.5 years of follow-up of patients needing retinal photocoagulation was 0.45 (95% CI 0.23–0.86) in the intensively treated group compared to the control group. The Fenofibrate Intervention and Event Lowering in Diabetes (FIELD) study[16] assessed the tolerability and efficacy of fenofibrate compared to placebo in 9,795 50- to 75-year-olds with type 2 DM. A first laser treatment for retinopathy was needed significantly less often in the fenofibrate group (3.4%) than the placebo group (4.9%) (p=0.0002); intriguingly, this was independent of plasma lipid changes. Fenofibrate may have relevant anti-apoptotic and anti-inflammatory properties. However, FIELD was not powered primarily for ophthalmic outcomes. In the ACCORD study, adding fenofibrate to simvastatin led to a significant 40% reduction in the odds ratio for progression of DR, significantly more than the benefit of adding placebo to simvastatin.[17] It was suggested that fenofibrate should be considered in patients with 'pre-proliferative DR and/or macular oedema, or when there is early DR in the only or good eye'.[18] A trial on the use of fenofibrate for DMO, with functional and anatomical endpoints, is planned (clinicaltrials.gov identifier NCT01320345).

It is hypothesised that blockade of the renin–angiotensin pathway may have beneficial effects on DR independently of effects on BP. The EURODIAB Controlled Trial of Lisinopril in Insulin-Dependent Diabetes Mellitus (EUCLID) study examined the effect of lisinopril on progression of DR in patients with type 1 DM who were not hypertensive.[19] A non-statistically significant benefit was shown for progression of DR. Similarly, the Heart Outcomes Prevention Evaluation study (HOPE) found that ramipril did not significantly reduce the incidence of laser treatment of DR in patients with DM, although this was not a primary outcome.[20] In contrast, the DIRECT study was designed specifically to examine the effect of candesartan on DR. Patients with type 1 DM (3326)[21] and type 2 DM (1905)[22] were followed for a median of 4.75 years. In the type 1 DM cohort, candesartan significantly reduced the proportion having a three-step decline in DR grade from 16.0% to 10.5% after adjusting for blood pressure, though this became evident only after post-hoc analysis. In patients with type 2 diabetes, candesartan significantly increased the proportion with mild DR whose DR regressed, but had no significant effect on worse grades of DR, or on macular oedema. The findings may have been blunted as 28% of the placebo arm of the type 2 DM cohort started a renin-angiotensin blocker during the trial. What this evidence means for the management of DMO is unclear, but specific recommendations have been made for the primary prevention of DR in type 1 DM, and in the treatment of mild DR in type 2 DM. [23]

Several uncontrolled case series on glitazones and DMO report mixed findings. As part of the ACCORD-Eye study, 6,875 eyes were photographed at baseline; in 1,377 eyes the patient was on a glitazone.[24] There was no association with glitazone use and DMO but there were several unknown potentially confounding factors. While firm evidence of a detrimental role for glitazones in DMO is lacking, substitution of the glitazone with an alternative therapy may be considered worthwhile in patients with DMO.

## Is laser treatment still considered useful?

Laser therapy has been the mainstay of treatment since the Early Treatment Diabetic Retinopathy Study (ETDRS), in which focal or grid laser reduced the risk of moderate visual loss from 24% to 12% at three years, compared to observation.[25] In the ETDRS, only 17% gained one or more best corrected visual acuity (BCVA) lines, highlighting that the aim of laser treatment is not to improve vision, but to prevent visual loss. This should be explained carefully to patients. Results in subsequent studies, however, were better than in the ETDRS; it can be speculated that this is in part as glycaemic control has since improved: 40% in the ETDRS study had an HbA1c of over 10%. In a Diabetic

Retinopathy Clinical Research Network (DRCR) randomised trial comparing focal or grid macular laser with intravitreal triamcinolone for DMO,[26] after a three year follow-up only 8% of those treated with laser had lost three or more lines, while 26% gained three or more lines, although only 36% of those originally enrolled in the trial reached the three-year follow-up point. A 'real-world' study from London[27] on laser treatment for DMO found that a modifiable risk factor for visual loss is non-attendance.

## Do steroids have a role?

Steroids are thought to have a stabilising effect on the inner blood retinal barrier. The DRCR trial mentioned above compared intravitreal preservative free triamcinolone, at doses of 1 mg or 4 mg, with conventional laser treatment.[26] In the study, steroids produced an initial improvement, but at three years were not superior to laser therapy. Not unexpectedly, raised intraocular pressure and cataracts were significantly more common in the group treated with steroids.

## Are vascular endothelial growth factor antagonists effective in diabetic retinopathy?

Understanding vascular endothelial growth factor (VEGF) has transformed the management of age-related macular degeneration (AMD) and intraocular injections of VEGF antagonists will also revolutionise treatment of DMO. NICE draft guidance published in October 2012 supports intravitreal ranibizumab for DMO with a macular thickness of 400 um of more as measured by OCT.

The putative role of VEGF in DMO formed the basis of the DRCR protocol I, which investigated the tolerability and efficacy of intravitreal injections of ranibizumab (Lucentis) for DMO in 854 eyes.[28] At two years the mean BCVA improvement from baseline was significantly better with ranibizumab than with triamcinolone or sham. It is not known to what extent ischaemia influenced results. While there were no safety concerns with ranibizumab, the study was not powered for safety. It is pertinent to note that initial BCVA gains with ranibizumab were maintained with an average of two to three injections in year two. Other high quality evidence supports the use of ranibizumab for DMO, such as the RESOLVE, RESTORE, RIDE and RISE studies. The BOLT study investigated the use of bevacizumab (Avastin) for DMO.[29] Those with macular ischaemia were excluded. BCVA was significantly better after treatment with bevacizumab than with laser at 24 months.

Even as funding and capacity issues around use of ranibizumab and bevacizumab are discussed, clinical trials are proceeding on a new means of inhibiting VEGF. VEGF Trap-Eye is a fusion protein consisting of the Fc part of human IgG fused with parts of VEGF receptors. The DME And VEGF Trap-Eye: INvestigation of Clinical Impact (DA VINCI) trial is examining VEGF Trap-Eye for DMO.[30] As the affinity of VEGF Trap-Eye for VEGF-A is higher than that of native receptors, and as the resulting complex is stable, less-than-monthly dosing may in theory be possible without loss of efficacy.

Systemic safety has been raised as a concern for VEGF antagonism in general,[31] with regard to thromboembotic events. It should not be forgotten that VEGF also has important physiological roles,[32] such as maintaining retinal neuron health.[33]

## Possible treatments to come for diabetic retinopathy

Hyperglycaemia simultaneously stimulates several potentially pathogenic pathways in the retina,[34] offering targets of potential therapeutic value (Table 1). In DM advanced glycation end-products (AGEs) accumulate and their receptors are activated.[35] Agents under evaluation in models of DR include pimagedine, aminoguanidine, and drugs that scavenge reactive intermediates of the pathway preventing AGE formation; molecules that break already cross-linked protein to fragments that can be cleared renally, and agents that block AGE receptors. In hyperglycaemia aldose reductase (AR) activity is increased.[36] Polymorphisms in the gene for AR have been associated with increased susceptibility to DR progression. AR reduces glucose to sorbitol which results in potentially adverse effects, including

**Table 1. A summary of possible future treatments for diabetic retinopathy.**

| Agent | Mechanism | Comments | Reference |
|---|---|---|---|
| Pimagedine | Inhibits AGE formation | In a randomised placebo-controlled trial pimagedine significantly slowed rate of progression of DR. | Bolton *et al*[40] |
| Sorbinol | Aldose reductase inhibitor | In a randomised placebo-controlled trial sorbinol failed to significantly retard progression of DR (though more potent AR inhibition may be required than used in the trial).[36] | Sorbinol Retinopathy Trial Research Group[41] |
| Ruboxistaurin | PKCβII inhibitor | Following an open-label extension of a randomised placebo-controlled trial, at 6 years those with the greater exposure to ruboxistaurin had a significantly lower risk of moderate visual loss. | Sheetz *et al*[37] |

AGE = advanced glycation end-product; AR = aldose reductase; DR = diabetic retinopathy; PKC = protein kinase C.

increased intracellular hypertonicity; production of fructose, which is in turn converted to glycosylating agents that contribute to AGE formation; and finally consumption of antioxidant defences. It is not known which effects of polyol pathway activation, if any, play a role in DR. Finally, de novo synthesis of diacylglycerol results from hyperglycaemia, leading to activation of several protein kinase C (PKC) isoforms.

Such molecular changes may be the basis of the decrease in retinal blood flow observed in early DM. Hypoperfusion may contribute to retinal hypoxia, thought to lead to low grade chronic inflammation and capillary dropout. As consequent production of VEGF leads to leakiness and aberrant neovascularisation, future interventions in early DR may be pro-angiogenic.[34] Promotion of controlled reperfusion of ischaemic areas before sequelae of ischaemia have developed may be a viable strategy.[38] Intravitreal injection of autologous haematopoeitic stem cells have been studied in animal models of ischaemic retinopathy, though there are challenges to overcome.

While hypoperfusion is a feature of early DM, a switch to hyperperfusion occurs later[34] and is associated with the first clinical signs of DR: microaneurysms. New technologies may allow identification of retinal arteriolar dilatation as a marker for DR onset.[39] Hyperperfusion and shear stress may exacerbate capillary loss and macular ischaemia. Furthermore a hyperdynamic circulation may lead to a net outflow of fluid, possibly contributing to DMO. The beneficial effect on DMO of controlling hypertension supports this hypothesis.

## Conclusion

Lessons of the past have served well in the management of diabetic maculopathy. The importance of control of systemic risk factors and the benefits of laser treatment should not be forgotten in the era of intravitreal injections. Anti-VEGF treatment may revolutionise both therapeutic outcomes and, by necessity, the organisation of DR services. However, in parallel with the inexorable rise in prevalence of DM, new avenues of understanding are opening up, raising the potential of novel treatments for DR.

## Disclosure

Dr Williams has received travel support from Novartis, Bayer, Allergan and Bausch and Lomb.

Professor Chakravarthy has served on advisory boards to Pfizer, Oraya Therapeutics, Allergan and Novartis, and received honoraria and travel support. She has been, and continues to be, an investigator on controlled clinical trials and observational studies sponsored by Pfizer, Novartis, Alcon and Bausch and Lomb and her department has received funds for the conduct of these studies.

Dr Williams conceived of and wrote the article; Professor Chakravarthy edited and advised on the text.

## Acknowledgements

The authors thank Anne Ramsay for photographic assistance.

## References

1 Al-latayfeh MM, Sun JK, Aiello LP. Ocular coherence tomography and diabetic eye disease. *Semin Opthalmol* 2010;25:192–7.
2 Yau JW, Rogers SL, Kawasaki R *et al.* Global prevalence and major risk factors of diabetic retinopathy. *Diabetes Care* 2012;35:556–64.
3 Romero-Aroca P, Fernandez-Alart J, Baget-Bernaldiz M *et al.* Diabetic retinopathy epidemiology in type II diabetic patients. Effect of the changes in the diagnostic criteria and stricter control of the diabetes between 1993 and 2005 on the incidence of diabetic retinopathy. *Arch Soc Esp Ofthalmol* 2007;82:209–18.
4 Scholl S, Augustin A, Loewenstein A *et al.* General pathophysiology of macular edema. *Eur J Opthalmol* 2010;21:10–19.
5 Wu M, Chen Y, Wilson K *et al.* Intraretinal leakage and oxidation of LDL in diabetic retinopathy. *Invest Ophthalmol Vis Sci* 2008;49:2679–85.
6 Barber AJ, Gardner TW, Abcouwer SF. The significance of vascular and neural apoptosis to the pathology of diabetic retinopathy. *Invest Ophthalmol Vis Sci* 2011;52:1156–63.
7 Rohan TE, Frost CD, Wald NJ. Prevention of blindness by screening for diabetic retinopathy: a quantitative assessment. *BMJ* 1989;299:1198–201.
8 Chan WC, Lim LT, Quinn MJ *et al.* Management and outcome of sight-threatening diabetic retinopathy in pregnancy. *Eye (Lond)* 2004;18:826–32.
9 Lancet. Intensive blood-glucose control with sulphonylureas or insulin compared with conventional treatment and risk of complications in patients with type 2 diabetes (UKPDS 33). UK Prospective Diabetes Study (UKPDS) Group. *Lancet* 1998;352:837–53.
10 BMJ. Tight blood pressure control and risk of macrovascular and microvascular complications in type 2 diabetes: UKPDS 38. UK Prospective Diabetes Study Group. *BMJ* 1998;317:703–13.
11 NEJM. The effect of intensive treatment of diabetes on the development and progression of long-term complications in insulin-dependent diabetes mellitus. The Diabetes Control and Complications Trial Research Group. *NEJM.* 1993;329:977–86.
12 Dluhy RG, McMahon GT. Intensive glycemic control in the ACCORD and ADVANCE trials. *NEJM* 2008;358:2630–3.
13 Ranjit Unnikrishnan I, Anjana RM, Mohan V. Importance of controlling diabetes early-the concept of metabolic memory, legacy effect and the case for early insulinisation. *The J Assoc Physicians India* 2011;59 Suppl:8–12.
14 Colhoun HM, Betteridge DJ, Durrington PN *et al.* Primary prevention of cardiovascular disease with atorvastatin in type 2 diabetes in the Collaborative Atorvastatin Diabetes Study (CARDS): multicentre randomised placebo-controlled trial. *Lancet* 2004;364:685–96.
15 Gaede P, Lund-Andersen H, Parving HH, Pedersen O. Effect of a multifactorial intervention on mortality in type 2 diabetes. *NEJM* 2008;358:580–91.
16 Keech AC, Mitchell P, Summanen PA *et al.* Effect of fenofibrate on the need for laser treatment for diabetic retinopathy (FIELD study): a randomised controlled trial. *Lancet* 2007;370:1687–97.
17 Matthews DR. Fenofibrate and statin therapy, compared with placebo and statin, slows the development of retinopathy in type 2 diabetes patients of 10 years duration: the ACCORD study. *Evid Based Med* 2011;16:45–6.
18 Wright AD, Dodson PM. Medical management of diabetic retinopathy: fenofibrate and ACCORD Eye studies. *Eye (Lond).* 2011;25:843–9.
19 Chaturvedi N, Sjolie AK, Stephenson JM *et al.* Effect of lisinopril on progression of retinopathy in normotensive people with type 1 diabetes. The EUCLID Study Group. EURODIAB Controlled Trial of Lisinopril in Insulin-Dependent Diabetes Mellitus. *Lancet* 1998;351:28–31.
20 Effects of ramipril on cardiovascular and microvascular outcomes in people with diabetes mellitus: results of the HOPE study and MICRO-HOPE substudy. Heart Outcomes Prevention Evaluation Study Investigators. *Lancet* 2000;355:253–9.
21 Chaturvedi N, Porta M, Klein R *et al.* Effect of candesartan on prevention (DIRECT-Prevent 1) and progression (DIRECT-Protect 1) of retinopathy in type 1 diabetes: randomised, placebo-controlled trials. *Lancet* 2008;372:1394–402.

22 Sjolie AK, Klein R, Porta M *et al.* Effect of candesartan on progression and regression of retinopathy in type 2 diabetes (DIRECT-Protect 2): a randomised placebo-controlled trial. *Lancet* 2008;372:1385–93.
23 Wright AD, Dodson PM. Diabetic retinopathy and blockade of the renin-angiotensin system: new data from the DIRECT study programme. *Eye (Lond)* 2010;24:1–6.
24 Ambrosius WT, Danis RP, Goff DC Jr, *et al.* Lack of association between thiazolidinediones and macular edema in type 2 diabetes: the ACCORD eye substudy. *Arch Ophthalmol* 2010;128:312–8.
25 Opthalmology. Early photocoagulation for diabetic retinopathy. ETDRS report number 9. Early Treatment Diabetic Retinopathy Study Research Group. *Ophthalmology* 1991;98:766–85.
26 Beck RW, Edwards AR, Aiello LP *et al.* Three-year follow-up of a randomized trial comparing focal/grid photocoagulation and intravitreal triamcinolone for diabetic macular edema. *Arch Ophthalmol* 2009;127:245–51.
27 Jyothi S, Sivaprasad S. Five-year visual outcome following laser photocoagulation of diabetic macular oedema. *Eye (Lond)* 2011;25:851–8; quiz 59.
28 Elman MJ, Bressler NM, Qin H *et al.* Expanded 2-year follow-up of ranibizumab plus prompt or deferred laser or triamcinolone plus prompt laser for diabetic macular edema. *Ophthalmology* 2011;118:609–14.
29 Rajendram R, Fraser-Bell S, Kaines A *et al.* A 2-Year Prospective Randomized Controlled Trial of Intravitreal Bevacizumab or Laser Therapy (BOLT) in the Management of Diabetic Macular Edema: 24-Month Data: Report 3. *Arch Ophthalmol* 2012;130:972–9.
30 Do DV, Schmidt-Erfurth U, Gonzalez VH *et al.* The DA VINCI Study: phase 2 primary results of VEGF Trap-Eye in patients with diabetic macular edema. *Ophthalmology* 2011;118:1819–26.
31 Lim LS, Cheung CM, Mitchell P, Wong TY. Emerging evidence concerning systemic safety of anti-VEGF agents-should ophthalmologists be concerned? *Am J Ophthalmol* 2011;152:329–31.
32 Senger DR. Vascular endothelial growth factor: much more than an angiogenesis factor. *Mol Biol Cell* 2010;21:377–9.
33 Sait-Geniez M, Maharaj AS, Walshe TE *et al.* Endogenous VEGF is required for visual function: evidence for a survival role on muller cells and photoreceptors. *PLOS One* 2008;3:e3554.
34 Curtis TM, Gardiner TA, Stitt AW. Microvascular lesions of diabetic retinopathy: clues towards understanding pathogenesis? *Eye (Lond)* 2009;23:1496–508.
35 Stitt AW. AGEs and diabetic retinopathy. *Invest Ophthalmol Vis Sci* 2010;51:4867–74.
36 Lorenzi M. The polyol pathway as a mechanism for diabetic retinopathy: attractive, elusive, and resilient. *Experimental diabetes research* 2007;2007:61038.
37 Sheetz MJ, Aiello LP, Shahri N *et al.* Effect of ruboxistaurin (RBX) on visual acuity decline over a 6-year period with cessation and reinstitution of therapy: results of an open-label extension of the Protein Kinase C Diabetic Retinopathy Study 2 (PKC-DRS2). *Retina Philadelphia, Pa* 2011;31:1053–9.
38 Stitt AW, O'Neill CL, O'Doherty MT *et al.* Vascular stem cells and ischaemic retinopathies. *Prog Retin Eye Res* 2011;30:149–66.
39 Rogers SL, Tikellis G, Cheung N *et al.* Retinal arteriolar caliber predicts incident retinopathy: the Australian Diabetes, Obesity and Lifestyle (AusDiab) study. *Diabetes care* 2008;31:761–3.
40 Bolton WK, Cattran DC, Williams ME *et al.* Randomized trial of an inhibitor of formation of advanced glycation end products in diabetic nephropathy. *Am J Nephrol* 2004;24:32–40.
41 A randomized trial of sorbinol, an aldose reductase inhibitor, in diabetic retinopathy. Sorbinol Retinopathy Trial Research Group. *Arch Ophthalmol* 1990;108:1234–44.


**Address for correspondence: Dr MA Williams, Ground Floor, Eye and Ear Clinic, Royal Victoria Hospital, Belfast BT12 6BA. Email: mwilliams11@qub.ac.uk**