

Lesson of the month 2: Cough and right hypochondrial discomfort

Authors: Hariney Kurunadalingam,^A Simon W Dubrey^B and Peter L Chiodini^C

ABSTRACT

Cystic echinococcosis, commonly known as hydatid disease, is caused by the larval stage of the tapeworm *Echinococcus granulosus*. Humans are an accidental host to this rare disease in the UK, with around 10–20 new cases reported each year. Once suspected, the diagnosis is confirmed through a combination of relevant history, imaging studies and serological testing. This lesson presents a case of hydatid disease and outlines the significant management issues when cysts rupture and the disease becomes disseminated.

KEYWORDS: Hydatid disease, *Echinococcus*, liver cysts

Case presentation

A 43-year-old South-Asian man presented with a three-week history of dry cough, fever, 2-kg weight loss and right hypochondrial discomfort. Past history included hepatic surgery in Pakistan 17 years earlier for an unknown reason. He denied alcohol consumption or smoking.

On examination, he appeared cachectic and was mildly febrile at 37.7°C, tachycardic at 126 beats/min and a blood pressure of 110/77 mmHg. The abdomen was tender in the right upper quadrant without peritonism, a negative Murphy's sign and an old laparotomy scar. Blood tests showed haemoglobin of 14.6 g/dl, white cell count $12.4 \times 10^9/l$ and normal eosinophil count ($0.4 \times 10^9/l$). The CRP was markedly elevated at 145 mg/l (normal 0–7.9). Renal function was normal with liver function revealing a mildly elevated bilirubin 34 $\mu\text{mol/l}$ and gamma GT 58 IU/l, normal alkaline phosphatase, aspartate transaminase and alanine transaminase. A chest radiograph showed what appeared to be an abnormal cardiac silhouette (Fig 1).

Subsequent computerised tomography (CT) imaging revealed multiple large septated cysts within the liver, the largest extending into the right hemithorax and measuring 9×9×13 cm (Fig 2). Further cysts were noted adjacent to the spleen, along with

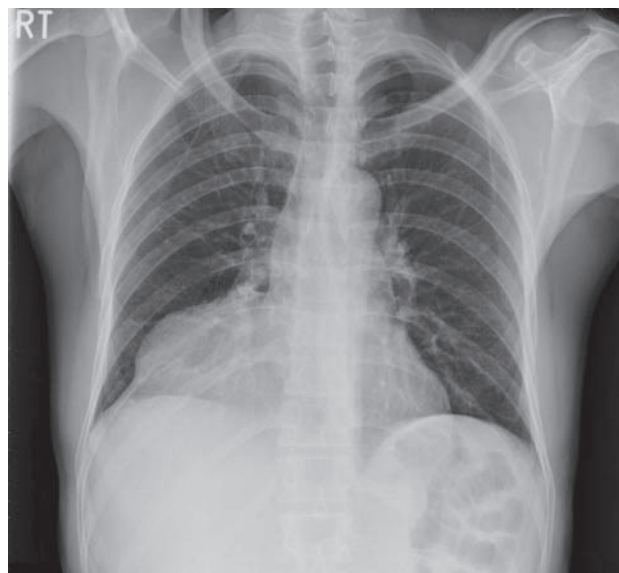


Fig 1. Chest radiograph showing an abnormal mass in the right lower hemithorax.

free fluid in the abdomen and a right pleural effusion. These appearances were considered indicative of widespread intra-abdominal WHO CE type 2 hydatid disease with likely cyst rupture. Hydatid serology was positive with an enzyme-linked immunosorbent assay (ELISA) value of 0.90 (normal cut off 0.25).

The patient initially received a nine-day course of piperacillin with tazobactam (4.5g tds) to cover biliary sepsis, and was subsequently commenced on albendazole (400 mg bd) with a view to a prolonged course of therapy to treat hydatid disease. He represented seven months later with a marked clinical deterioration, being pyrexial, jaundiced and neutropaenic, likely secondary to albendazole. CT scans demonstrated a reduction in size of the liver cysts but multiple additional cysts in the abdomen, including within the pancreas and in the pelvis. These appearances indicated disseminated intra-abdominal hydatid disease. Most recent follow up has determined that there is no cardiac or pericardial involvement. Any future treatment will now be based on any changes within the lesion as assessed by three-monthly scans, but is limited by the inability to give further albendazole therapy.

Authors: ^Afoundation year 2, Accident and Emergency, West Middlesex University Hospital, Isleworth, UK; ^Bconsultant cardiologist, Cardiology Department, Hillingdon Hospital, Uxbridge, UK; ^Cconsultant parasitologist, Hospital for Tropical Diseases, London, UK, and London School of Hygiene and Tropical Medicine, London, UK

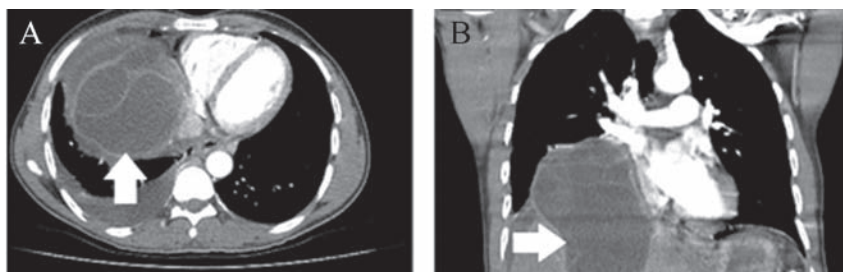


Fig 2. (A) Coronal and (B) sagittal section CT images of the thorax and upper abdomen. A large cystic mass (white arrows) is seen to arise within the liver and extend into the right hemithorax. CT = computerised tomography.

Discussion

Hydatid disease (cystic echinococcosis (CE)) is caused by the larval stage of the tapeworm *Echinococcus granulosus*. CE is the only type of echinococcosis indigenous to the UK. The natural hosts of *E granulosus* are domestic dogs or foxes with a common intermediate being sheep and an accidental host being humans. Hydatid disease is rare in the UK with around 10–20 new cases reported each year. Recognised UK foci include Wales and the Western Isles of Scotland.¹ However, most cases are likely to have arisen from exposure abroad. The liver is the most commonly affected organ,² but almost any organ can become involved. Symptoms depend on the location and size of the cyst and whether or not it leaks (dissemination, risk of anaphylaxis), ruptures or becomes secondarily infected.

The diagnosis is made by a combination of appearances on imaging (ultrasound, CT scan or MRI) and serological (usually ELISA, occasionally complement fixation) testing. Management is according to cyst type determined by the WHO ultrasound classification of liver hydatid cysts,³ as recommended by the WHO Informal Working Group on Echinococcosis.⁴ CE type-2 cysts are usually treated with a combination of albendazole and surgery, with the option to give perioperative praziquantel. A scolicidal agent (20% sodium chloride in the UK) is used to wash out the hydatid cavity at operation. Depending on the case, surgery can range from liver resection, radical pericystectomy or cystectomy to de-roofing of the cyst.⁵ Long-term benzimidazole therapy with albendazole or mebendazole is appropriate for patients with disseminated disease where surgery is not an option.⁶ Albendazole is usually preferred. The adult dose is 400 mg twice daily. It is no longer considered necessary to administer albendazole in 28-day blocks with two-week intervals between them.^{7,8} As yet there are no vaccines to protect humans from this disease. Good animal husbandry and regular de-worming of dogs are the mainstay of prevention.

Key points

- > Hydatid disease is unusual in the UK, with around 10–20 new cases reported per year.
- > Most cases arise from travel abroad.

- > Complications include cyst rupture, dissemination, risk of anaphylaxis and secondary infection.
- > Management is according to cyst type determined by the WHO ultrasound classification of liver hydatid cysts.⁴
- > Albendazole is the recommended treatment, with the addition of benzimidazole for disseminated disease. ■

Acknowledgement

PLC is supported by the National Institute for Health Research UCL Hospitals Biomedical Research Centre.

References

- 1 Public Health England. *Background information on Hydatid disease*. London: PHE, 2011. Available online at <http://webarchive.nationalarchives.gov.uk/20140714084352/http://www.hpa.org.uk/Topics/InfectiousDiseases/InfectionsAZ/HydatidDisease/GeneralInformation/hyd010BackgroundInformation/> [Accessed 5 February 2015].
- 2 Lewall DB. Hydatid disease: Biology, imaging and classification. *Clin Radiol* 1988;53:863–74.
- 3 Group WIW. International classification of ultrasound images in cystic echinococcosis for application in clinical and field epidemiological settings. *Acta Trop* 2003;85:253–61.
- 4 Brunetti E, Kern P, Vuitton DA, Writing Panel for the WHO-IWGE. Expert consensus for the diagnosis and treatment of cystic and alveolar echinococcosis in humans. *Acta Trop* 2010;114:1–16.
- 5 Silva MA, Mirza DF, Bramhall SR *et al*. Treatment of hydatid disease of the liver: evaluation of a UK experience. *Dig Surg* 2004;21:227–34.
- 6 Shams-Ul-Bari, Arif SH, Malik AA. Role of albendazole in the management of hydatid cyst liver. *Saudi J Gastroenterol* 2011;17:343–7.
- 7 Guidelines for treatment of cystic and alveolar echinococcosis in humans. WHO Informal Working Group on Echinococcosis. *Bull World Health Organ* 1996;74:231–42.
- 8 Franchi C, Di Vico B, Teggi A. Long-term evaluation of patients with hydatidosis treated with benzimidazole carbamates. *Clin Infect Dis* 1999;29:304–9.

Address for correspondence: Dr S Dubrey, Department of Cardiology, Hillingdon Hospital, Field Heath Road, Uxbridge UB8 3NN, UK.

Email: simon.dubrey@thh.nhs.uk