

A case of dapsone-induced methaemoglobinaemia

Authors: Yee Ann Tan,^A Kai Choon Ng,^A Seng Wee Cheo,^B Tee Tat Khoo^C and Qin Jian Low^D

ABSTRACT

Methaemoglobinaemia is an uncommon but potentially serious condition. It can be caused by congenital or acquired cause. Drug-induced methaemoglobinaemia is the commonest cause of acquired methaemoglobinaemia. The clinical signs and symptoms of methaemoglobinaemia include dyspnoea, desaturation, presence of saturation gap, headache, nausea and seizures depending on level of serum methaemoglobinaemia. We illustrate a case of dapsone-induced methaemoglobinaemia and its successful treatment by intravenous methylene blue.

KEYWORDS: Dapsone, methaemoglobinaemia

DOI: 10.7861/clinmed.2020-0364

Introduction

Methaemoglobinaemia is a life-threatening condition that causes impairment of tissue oxygenation and yet it's easily missed. It can be caused by inherited or acquired causes. Acquired cause of methaemoglobinaemia is more common and its often caused by various drugs and toxins.¹ On the other hand, dapsone is a widely available medicine, commonly used for leprosy, acne vulgaris, dermatitis herpetiformis, pemphigoid and occasionally as prophylaxis for *Pneumocystis carinii* pneumonia. A well-known yet uncommon side effect of dapsone is methaemoglobinaemia. Here, we illustrate a case of methaemoglobinaemia secondary to dapsone.

Case presentation

A 36-year-old man with newly diagnosed HIV infection, presented with fever and cough for 2 months associated with reduced effort tolerance. His chest X-ray on admission showed bilateral reticular opacities. He was diagnosed with *Pneumocystis Carinii* pneumonia (PCP) and started on trimethoprim/sulfamethoxazole (Bactrim) for treatment of PCP. Unfortunately, he developed severe skin reaction after starting Bactrim and required treatment interruptions. He was then switched to primaquine and clindamycin in view of Bactrim allergy.

His hospitalisation had been otherwise uneventful apart from acute kidney injury where his creatinine level increased from baseline 72 µmol/L to 130 µmol/L. Otherwise, he managed to complete 21 days of PCP treatment. On completion of PCP treatment, he was given oral dapsone 100 mg twice daily for PCP prophylaxis in view of allergy history to Bactrim. On the second day of dapsone, he complained of sudden onset of dyspnoea. Upon assessment, he was cyanosed and tachypnoeic with respiratory rate of 38 breaths per minute. His blood pressure was 120/69 mmHg, pulse rate was 85 beats per minute, oxygen saturation was recorded 85% on room air. Lung examination was clear with equal air entry bilaterally.

Diagnosis

He was suspected to have methaemoglobinaemia in view of cyanosis and recent history of dapsone. Differential diagnosis to be considered include pneumonia, pulmonary embolism and pneumothorax.

Initial management

He was started on high-flow oxygen and placed under close monitoring while waiting for investigation. Investigations included full blood count, reticulocyte count, arterial blood gases and chest X-ray. His saturation did not improve despite high-flow oxygen.

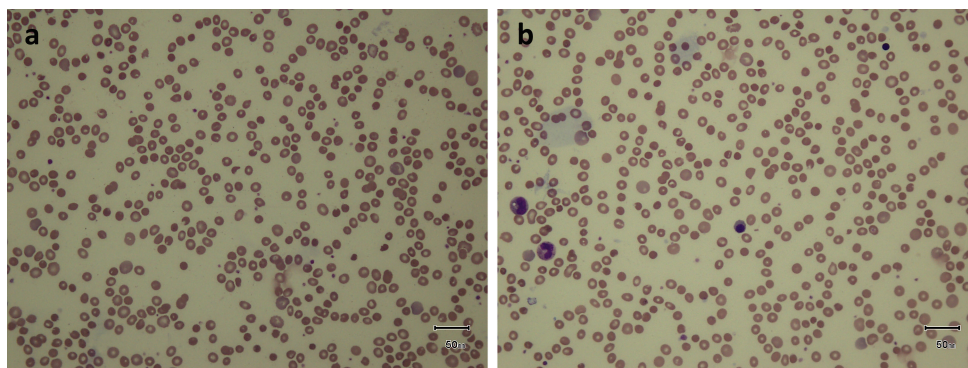
Case progression and outcome

His blood investigations showed evidence of haemolysis with his haemoglobin level reduced to 7 g/dL from 10 g/dL previously and reticulocyte count of 10%. His peripheral blood film showed presence of irregularly contracted cells with occasional blister cells, suggestive of oxidative haemolysis (Fig 1). His arterial blood gas under high-flow oxygen showed pH 7.405, partial pressure of carbon dioxide (pCO₂) 30.4 mmHg, partial pressure of oxygen (pO₂) 241.4 mmHg, bicarbonate 19.2 mmol/L, base excess -5.7 mmol/L. Chest X-ray did not show any new changes.

An urgent methaemoglobin (MetHb) level was done, it was 8.4%, which confirmed the diagnosis of methaemoglobinaemia. He was given intravenous methylene blue 1 mg/kg over 5 minutes and transfused 2 pints of packed cells. His condition improved remarkably after transfusion and intravenous methylene blue (Fig 2). Repeated serum methaemoglobin level reduced to 3.1%. Haemoglobin level improved to 9 g/dL after blood transfusion. He was later discharged well and was then given nebulised pentamidine for PCP prophylaxis.

Authors: ^Aphysician, Queen Elizabeth Hospital, Kota Kinabalu, Malaysia; ^Bphysician, Lahad Datu Hospital, Lahad Datu, Malaysia; ^Cphysician, Segamat Hospital, Segamat, Malaysia; ^Dphysician, Sultanah Nora Ismail Hospital, Batu Pahat, Malaysia

Fig 1. Peripheral blood film showing presence of irregularly contracted cells with occasional blister cells. Mild neutrophilia. Neutrophils show toxic granulations with cytoplasmic vacuolation. Overall features suggestive of oxidative haemolysis.



Discussion

Methaemoglobin is an aberrant state of haemoglobin in which the ferrous (Fe^{++}) ions of haeme are oxidized to the ferric (Fe^{+++}) state. The ferric haeme molecules of MetHb are unable to reversibly bind oxygen, impairing their ability to unload oxygen to tissues, thus causing the oxygen dissociation curve to be 'left shifted' and eventually causing a state of functional anaemia.² Normally, erythrocytes produce low levels of MetHb, keeping it less than 1%, with 99% of haemoglobin in the ferrous state.²

In general, most cases of methaemoglobinaemia are acquired and dapsone is one of the most common drugs that causes

methaemoglobinaemia. Other causes including lidocaine, benzocaine, sulfonamides or environmental agents such as pesticides and industrial nitrates.^{3,4} Dapsone is a synthetic sulfone with anti-inflammatory, immunosuppressive properties and antibiotic properties. It is sometimes used as an alternative agent in patients who are unable to tolerate trimethoprim/sulfamethoxazole.⁵

Clinical symptoms and serum MetHb level can guide the diagnosis of methaemoglobinaemia. One should always suspect methaemoglobinaemia if a patient has hypoxia or cyanosis after ingestion of dapsone and the hypoxia does not improve with an increased administration of oxygen. Beside that, the patients will have normal arterial pO_2 in the presence of cyanosis or presence of a saturation gap. Central and peripheral cyanosis are usually seen at a serum MetHb level of 15%. MetHb levels of 30–45% will result in headache, nausea and weakness, while 60% result in arrhythmia, dyspnea and seizures. Death usually occurs if MetHb is recorded at more than 70%.⁶

Initial treatment for acquired methaemoglobinaemia is to discontinue the offending drug.³ Patients with symptomatic or severe degrees of methaemoglobinaemia (>20%) should be treated with intravenous methylene blue 1–2 mg/kg over 5 minutes, the dose may be repeated in 1 hour if the level of MetHb is still high. Ascorbic acid is an effective alternative agent if methylene blue is not available.⁵ In this case, intravenous methylene blue 1 mg/kg was given to the patient as he was symptomatic. After methylene blue and optimisation of haemoglobin, his condition improved.

Conclusion

Methaemoglobinaemia is an uncommon but yet potentially life-threatening complication of dapsone. Presence of cyanosis, saturation gap and history of recent new medication should prompt clinicians to raise the suspicion of methaemoglobinaemia. It is highly reversible by intravenous methylene blue.

Key points

- > Methaemoglobinaemia is a potentially life-threatening condition.
- > The presence of cyanosis, saturation gap and recent new medication should alert clinicians to suspect the diagnosis of methaemoglobinaemia.
- > Methaemoglobinaemia should be confirmed by serum methaemoglobin level.

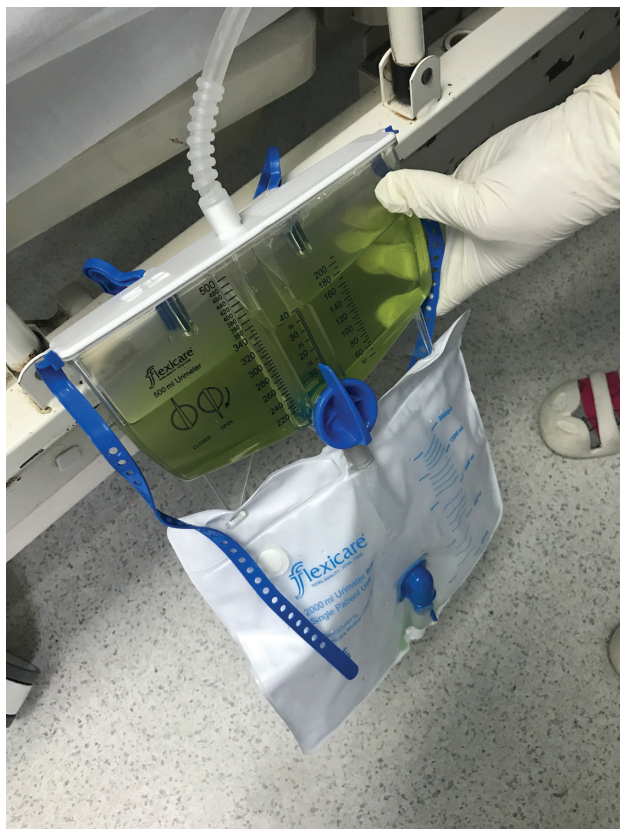


Fig 2. Photograph showing urine colour that has turned green-blue after intravenous methylene blue.

- > The symptoms of methaemoglobinaemia can vary depending on the level of serum methaemoglobin.
- > Dapsone is an important and common cause of methaemoglobinaemia.
- > Acquired methaemoglobinaemia is easily reversible by administration of methylene blue. ■

References

- 1 Burke P, Jahangir K, Kolber MR. Dapsone-induced methemoglobinemia: case of the blue lady. *Can Fam Physician* 2013;59: 958–61.
- 2 Ludlow JT, Wilkerson RG, Sahu KK, Nappe TM. Methemoglobinemia. In: *StatPearls*. Treasure Island: StatPearls Publishing, 2020. www.ncbi.nlm.nih.gov/books/NBK537317
- 3 Jose B, Jose JV, Paul M. Dapsone-Induced methemoglobinemia: Blue cures blue. *J Pharmacol Pharmacother* 2018;9:117–20.
- 4 Valsan A, Sharma S, Mathew R, Chengappa A. Dapsone-induced methemoglobinemia: Two cases and a short review. *J Appl Hematol* 2018;9:29–32.
- 5 Barclay JA, Ziemba SE, Ibrahim RB. Dapsone-induced methemoglobinemia: a primer for clinicians. *Ann Pharmacother* 2011;45: 1103–15.
- 6 Singh S, Sethi N, Pandith S, Ramesh GS. Dapsone-induced methemoglobinemia: "Saturation gap" The key to diagnosis. *J Anaesthesiol Clin Pharmacol* 2014;30:86–8.

Address for correspondence: Dr Seng Wee Cheo, Department of Internal Medicine, Lahad Datu Hospital, Peti Bersurat 60065, 91110 Lahad Datu, Sabah, Malaysia.
Email: cheosengwee@gmail.com



Royal College
of Physicians

COVID-19 and pandemic management

A **new** *Clinical Medicine* and
Future Healthcare Journal
subject collection

Articles relating to the COVID-19 pandemic are
now gathered together in one handy online
subject collection for you to browse.

Browse the collection:

www.rcpjournals.org/covid-19