

Images of the month 2: Disseminated nocardiosis in a 60-year-old woman with sarcoidosis

Authors: Ofer Perzon^A and Hila Elinav^B

KEYWORDS: Nocardiosis, sarcoidosis

DOI: 10.7861/clinmed.2021-0745

Case presentation

A 60-year-old woman presented with fever, myalgia and painful subcutaneous nodules for 2 weeks. She had a history of pulmonary sarcoidosis, treated with prednisone 20 mg daily in the previous 3 months. Physical examination was remarkable for fever (38.7°C) and multiple tender subcutaneous and muscular nodules on her limbs. Laboratory abnormalities included leukocytosis (14,000 per mm³), neutrophilia (95%) and elevated C-reactive protein (12 mg/dL). Total body computed tomography (CT) revealed disseminated abscesses (Fig 1a and 1b) and magnetic resonance imaging (MRI) of the brain indicated occipital and frontal lesions (Fig 1c). Drainage of one nodule resulted in pus that was negative on microscopy, but 5 days later colonies of filamentous Gram-positive branching rods appeared on chocolate agar identified as *Nocardia brasiliensis* (Fig 1d). The patient was diagnosed with disseminated nocardiosis and was treated with high-dose trimethoprim–sulfamethoxazole, and linezolid later switched to minocycline due to myelosuppression, resulting in dramatic clinical, laboratory and radiological improvement after 4 months. ■

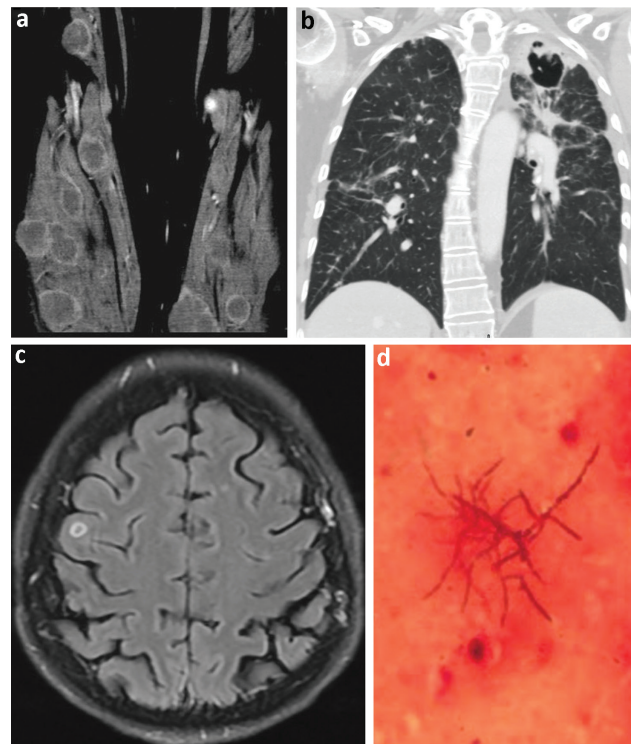


Fig 1. a) Coronal computed tomography section of the limbs, showing multiple subcutaneous and muscular abscess. b) Coronal computed tomography section of the lungs, showing left upper lobe cavitary lesion. c) Axial magnetic resonance imaging of the brain, showing a frontal lobe small ring enhanced lesion. d) Filamentous Gram-positive branching rods on chocolate agar.

Authors: ^Aresident in internal medicine, Hadassah Hebrew University Medical Center, Jerusalem, Israel; ^Bspecialist in infectious diseases, Hadassah Hebrew University Medical Center, Jerusalem, Israel

Address for correspondence: Dr Ofer Perzon, Internal Medicine B Department, Hadassah Hebrew University Medical Center, Kalman Ya'akov Man Street, Jerusalem, Israel.
Email: ofer.perzon@gmail.com