

## Diagnosing and managing mononeuropathies

Geraint Fuller MD FRCP, Consultant Neurologist, Gloucester Royal Hospital

*Clin Med* 2004;4:113–17

Lesions to single peripheral nerves are common, provide considerable diagnostic difficulty and their management can be difficult. Many patients will present to neurologists, orthopaedic surgeons or rheumatologists, but many others are seen by general physicians. This article will explore some common and some rarer, though important, mononeuropathies, discuss the diagnosis, differential diagnosis and management. (Excellent reference books are available.<sup>1,2</sup>)

### Background

Investigation and management have evolved based on a number of general principles with only limited support from clinical trials. Different peripheral nerves have different susceptibilities according to their anatomy, but all mononeuropathies arise from four principal mechanisms (Table 1).

Regardless of cause, there are essentially three types of focal peripheral nerve lesion:

- neuropraxia, a focal or segmental demyelination with preservation of the axon and recovery in 2–12 weeks
- axonotmesis, in which the axon is divided but the epineurium remains intact and regrows at 1 mm per day from the site of injury
- neurotmesis where the nerve is divided and no longer in continuity, with no recovery.

They can occur in combination, as can be appreciated clinically, with relatively rapid recovery (neuropraxic recovery) followed by a period of slower recovery (axonotmesis). An appreciation of the

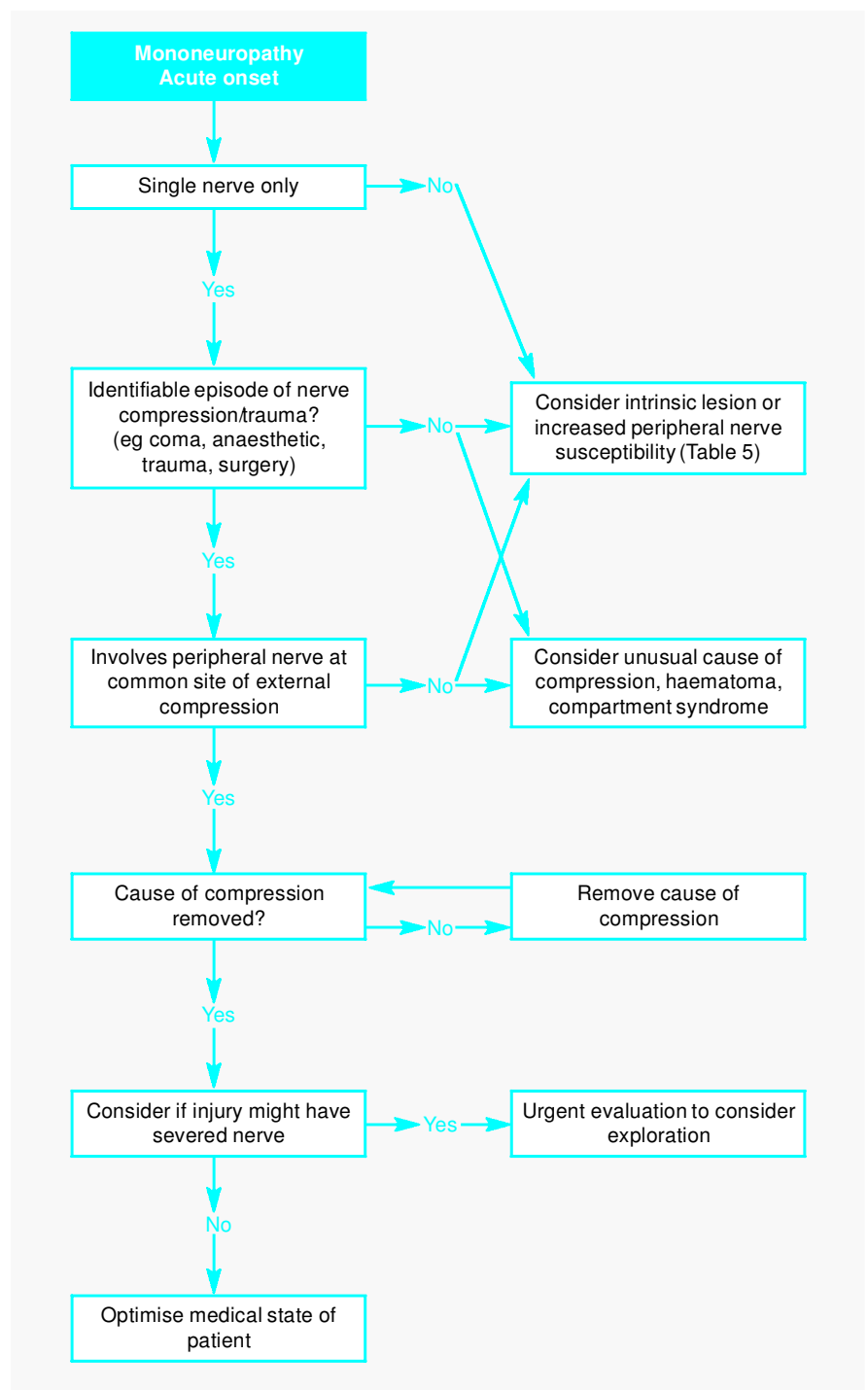


Fig 1. Investigation of acute onset mononeuropathies.

likely mechanism of nerve injury will guide investigation and management of the patient.

### Is it a mononeuropathy?

Making the diagnosis of a mononeuropathy depends on recognising that the neurological deficit lies within the distri-

bution of a single nerve. This in turn requires knowledge both of peripheral nerve anatomy and of the motor and sensory territories of each nerve. Fortunately, relatively few nerves are particularly prone to mononeuropathies, and mononeuropathies of these nerves occur frequently (Table 2). In addition, a few uncommon mononeuropathies may

present diagnostic or management problems on the medical take (Table 3). There are others that are rare but worth being aware of, as recognition may allow appropriate further assessment (Table 4).

Peripheral nerves are arranged in fascicles so a more proximal lesion may be mistaken for a more distal lesion. For example, patients can occasionally develop a foot drop following hip replacement, with weak eversion and preserved inversion and sensory loss in the common peroneal nerve distribution. However, this is almost certainly a sciatic lesion at the level of the hip involving the common peroneal fascicle rather than a more distal common per-

oneal nerve lesion, for example one at the fibular head.

## Investigations and management of mononeuropathies

Mononeuropathies can be broadly divided according to the speed of onset.

### Acute onset mononeuropathies

These can be divided into those where there is an identifiable external compression (eg ulnar, radial, common peroneal or sciatic lesions relating to a period of unconsciousness) and those where the mononeuropathy has occurred sponta-

neously. The former should prompt a screen for factors that might increase susceptibility to nerve injury, particularly history of toxins (especially alcohol), nutritional deficiencies, diabetes and thyroid disease. Such patients should be managed conservatively provided that the compressive lesion is removed. If there is any question that the nerve could have been divided, mainly as a result of trauma, expert assistance should be urgently obtained to determine whether to proceed to exploration and repair. Spontaneous mononeuropathies should be investigated aggressively for potential causes of intrinsic nerve damage (Table 5).<sup>3</sup>

Nerve conduction studies may be able to identify a more widespread neuropathy than is apparent clinically. However, acute changes in EMG that would be helpful to determine prognosis (to distinguish a neuropraxia from a more severe injury) take 10 days to two weeks to develop.

### Insidious onset mononeuropathies

Most insidious onset neuropathies relate to internal compression or repeated minor external compression. The history needs to be explored to find any activities that might lead to the latter. Examples are habitual leaning on the elbows

**Table 1. The principal mechanisms giving rise to peripheral neuropathies.**

Mononeuropathy	Mechanism
External insult	direct trauma, including prolonged external compression as occurs in prolonged unconsciousness, repeated minor trauma, traction, injection, cold, burns, radiation
Internal entrapment or compression	median entrapment in the carpal tunnel ulnar nerve at the elbow rarely, compression by tumours/deposits or vascular malformations
Intrinsic lesion to the nerve	eg an infarct, usually arising as a focal manifestation of a more generalised process, eg a nerve infarct due to vasculitis, an area of conduction block in multifocal motor neuropathy
Increased susceptibility to nerve injury	eg in diabetes, combined with minor entrapment or compression

**Table 2. Common neuropathies.**

Nerve	Site of lesion	Common causes	Motor deficit	Sensory deficit	Differential diagnosis
<b>Arm</b>					
Median	Carpal tunnel	Entrapment, diabetes, hypothyroidism, connective tissue disease	Abductor pollicis brevis, opponens pollicis	Thumb, index and middle finger	C6 or C7 radiculopathy Local pathologies
Ulnar	Elbow (cubital tunnel)	External compression, trauma (recent or distant)	Long flexors of little and ring fingers, finger abductors and adductors, lumbricals	Little and ring fingers	More distal or proximal ulnar lesion Motor neurone disease T1 lesions
<b>Leg</b>					
Lateral cutaneous nerve of the thigh	Inguinal ligament	Obesity, pregnancy, surgery	None	Lateral thigh	L2 radiculopathy
Common peroneal	Fibular head	External compression (leg crossing, iatrogenic), trauma	Foot dorsiflexion and eversion, toe extension	Lateral calf and dorsum of foot	L5 radiculopathies, proximal sciatic lesions Also upper motor neurone weakness and motor neurone disease

producing an ulnar lesion or habitual kneeling producing a common peroneal lesion. The many, usually outdated occupational mononeuropathies are reminders of these (eg 'strawberry picker's' = common peroneal at knee,

'pitchfork' = suprascapular nerve at the shoulder). Modern equivalents might relate to mountain bikers damaging the ulnar nerve in the hand and backpackers who can damage the suprascapular nerve (Table 4). If any such repeated external

compression is identified, the relevant activity should be avoided. Recovery will depend on the severity of the lesion, though it is usually a combined neuropraxia and axonotmesis because these nerves are in continuity.

**Table 3. Less common mononeuropathies.**

Nerve	Site of lesion	Common causes	Motor deficit	Sensory deficit	Differential diagnosis
<b>Arm</b>					
Radial	Upper arm, spiral groove	External compression, trauma	Finger and wrist extensors, some weakness of brachioradialis	Anatomical snuffbox	C7 radiculopathy
Axillary	Humeral head	Trauma, fracture of humeral head	Deltoid	Lateral shoulder	
<b>Leg</b>					
Femoral		Psoas haematoma, iatrogenic injury, trauma	Hip flexion, knee extension	Anterior thigh, medial calf	L3, L4 radiculopathies, diabetic amyotrophy
Sciatic	Pelvis, buttock or thigh	Trauma, compression in buttock, tumour, injection	Hamstrings plus common peroneal and tibial nerve deficits	Posterior cutaneous nerve of thigh plus common peroneal plus posterior tibial	L5, S1 radiculopathies

**Table 4. Rare mononeuropathies.**

Nerve	Site of lesion	Common causes	Motor deficit	Sensory deficit	Differential diagnosis
<b>Arm</b>					
Ulnar	Wrist (Guyon's canal) or hand	Compression (cycling), entrapment	Wrist: adductor pollicis, interosseous muscles, hypothenar muscles Hand: adductor pollicis, interosseous muscles	Wrist and medial half of ring finger Lesions in the hand: none	Motor neurone disease, syringomyelia, T1 radiculopathy
Long thoracic	Not clear	Usually unknown, trauma	Serratus anterior Winging of scapular	None	Neuralgic amyotrophy
Anterior interosseous branch of median nerve	Just below the elbow	Fibrous bands, trauma	Flexor pollicis longus, flexor digitorum profundus of index finger (loss of pinch sign), pronator quadratus		
Posterior interosseous branch of radial nerve	As nerve enters supinator muscle	Entrapment, trauma	Finger extensors: finger drop without wrist drop	None	C7 radiculopathy, upper motor neurone lesions, neuralgic amyotrophy
Suprascapular	Suprascapular notch	Trauma, lifting (rucksack)	Supraspinatus and infraspinatus	None	Shoulder pathology, neuralgic amyotrophy
<b>Leg</b>					
Saphenous	Thigh or knee	Knee surgery or arthroscopy	None	Medial calf	
Posterior cutaneous nerve of the thigh		Compression, trauma	None	Posterior calf	S3, S4 radiculopathy
Obturator	Obturator foramen	Obturator hernia, pelvic tumours, surgery	Adductors of the hip	Medial thigh	Lumbosacral plexopathy

If no such external compression is identified, an internal entrapment needs to be sought. Most are at common sites of entrapment. Neurophysiology can prove helpful in determining the site of entrapment for some nerves. If a nerve is producing significant problems, exploration of the site of entrapment and release is the usual intervention.

## Specific mononeuropathies

### Median nerve

Median nerve lesions are most common, with a 3–5% prevalence depending on case definition. Most will arise due to compression in the carpal tunnel. The diagnosis is often straightforward, but in many cases there is uncertainty. There are many ‘diagnostic tests’, for example Tinel’s and Phalen’s signs, which, though widely used, have not been discriminant in clinical studies.<sup>4</sup> Clinical tests found to be predictive of neurophysiological evidence of a median nerve lesion at the wrist include:

- hyperalgesia in the median nerve territory
- classic Katz hand diagram (where the patient draws the area of sensory loss), and
- weakness of abductor pollicis brevis.<sup>4</sup>

Cochrane reviews have found some support for oral steroids, splinting, ultrasound and yoga in mild cases.<sup>5</sup> Steroid injections improve outcome at one month compared with placebo and at

three months compared with oral steroids. However, at six months no benefit was found with non-steroidal anti-inflammatory drugs and splinting.<sup>6</sup> Surgery has better results than splinting.<sup>7,8</sup> It is not clear whether patients with severe lesions benefit from surgery.

Patients who have associated problems that will pass or can be treated effectively, for example pregnancy or hypothyroidism, will usually be managed conservatively and reviewed according to response.

### Ulnar nerve

This is a common mononeuropathy, particularly in those who have been bed-bound or unwell. The diagnosis is usually straightforward clinically. Recognition of weakness in the long flexors of the little and ring fingers indicates that the lesion is above the wrist and likely to be at the elbow. There is no clear evidence as to when or how to intervene, though most patients would be offered decompression, with or without transposition, if they had significant signs and were not improving having avoided repeated minor trauma to the nerve at the elbow.

### Radial nerve

The most commonly seen acute mononeuropathy is that affecting the radial nerve. It presents after deep sleep or coma, particularly (though not exclusively) alcohol induced, the so-called ‘Saturday night’ palsy that can be

mistaken for other causes of weakness. The difficulty in assessment relates to a misinterpretation of weakness in the hand. The weakness of wrist and finger extension prevents the ulnar and median innervated muscles from being tested as this is a mechanically disadvantaged position. Placing the hand palm down on a flat surface will allow isolated assessment of finger abduction and adduction (which will prove to be normal); placing the hand palm up on a flat surface will allow testing of abductor pollicis brevis. Weakness is most commonly found in brachioradialis with normal power in triceps because the most common site for radial compression lies between the branches to these two muscles. The rare posterior interosseous nerve leads to finger drop without wrist drop.

Radial palsies need to be distinguished from C7 radiculopathies; the differing sensory distributions can be helpful, though this differential can be difficult.

### Axillary nerve, suprascapular nerve and long thoracic nerves

Mononeuropathies in any of these nerves need to be distinguished from brachial neuritis (also referred to as neuralgic amyotrophy) which can predominantly affect this part of the brachial plexus. Brachial neuritis begins with severe pain, followed by weakness and prominent wasting. Finding of involvement of muscles not innervated by the specific nerve, either clinically or neurophysiologically, points to brachial neuritis as the diagnosis. Brachial neuritis will generally recover spontaneously, if slowly.

### Common peroneal nerve

The foot drop produced by the common peroneal nerve needs to be distinguished from the many other causes of foot drop, in particular an L5 radiculopathy. This nerve does not innervate tibialis posterior so inversion should be preserved. In a significant foot drop, the preservation of inversion strongly suggests a common peroneal nerve lesion; any weakness of inversion indicates a more proximal lesion than a common peroneal mononeuropathy.

**Table 5. Investigations.**

*To screen for increased peripheral nerve susceptibility:*

- Blood glucose
- Liver function tests
- Viscosity/ESR
- Vitamin B12
- Protein electrophoresis

*To look for causes of intrinsic mononeuropathies – those above plus:*

- Vasculitic screen (eg rheumatoid factor, ANCA, autoimmune profile, complement, cryoglobulin)
- Consider genetic testing for hereditary liability to pressure palsies

ANCA = antineutrophil cytoplasmic antibody; ESR = erythrocyte sedimentation rate.

## Key Points

Mononeuropathies can be mistaken for other neurological problems

Most mononeuropathies can be diagnosed clinically

The time course and mechanism of peripheral nerve injury determine the approach to investigation and treatment

The type of nerve injury determines the potential for recovery

Acute mononeuropathies can be the presentation for vasculitis

**KEY WORDS:** diagnosis, management, mononeuropathy

### Sciatic nerve

A weak leg in a patient who wakes from coma can be a source of confusion. Recognition that the weakness and sensory loss lies within the sciatic nerve distribution can be difficult particularly if the patient is unwell as a result of whatever caused the coma. However, an awareness of this possible diagnosis may prevent fruitless investigations elsewhere in the nervous system.

### Catches

Mononeuropathies can sometimes erroneously seem a reasonable explanation for a neurological deficit. For example, a patient with mild wasting in the small muscles of one hand, seeming to spare the thenar eminence with a prior history of elbow trauma, might be thought to have an ulnar nerve lesion at the elbow or in the hand, whereas in fact it relates to the onset of motor neurone disease. If the clinical problem does not behave as you expect, think again.

### References

- 1 Staal A, van Gijn J, Spaans F, Hasan D. *Mononeuropathies; examination, diagnosis and treatment*. London: WB Saunders, 1998.
- 2 Stewart JD. *Focal peripheral neuropathies*, 3rd edn. Baltimore: Lippincott, Williams and Wilkins, 2000.
- 3 Willison HJ, Winer JB. Clinical evaluation and investigation of neuropathy. *J Neurol Neurosurg Psychiatry* 2003;74(Suppl 2): ii3–ii8.
- 4 D'Arcy CA, McGee S. The rational clinical examination. Does this patient have carpal tunnel syndrome? Review. *JAMA* 2000; 283:3110–7.
- 5 O'Connor D, Marshall S, Massy-Westropp N. Non-surgical treatment (other than steroid injection) for carpal tunnel syndrome (Cochrane Review). In: *The Cochrane Library*, Issue 1, 2003. Oxford: Update Software.
- 6 Marshall S, Tardif G, Ashworth N. Local corticosteroid injection for carpal tunnel syndrome (Cochrane Review). In: *The Cochrane Library*, Issue 1, 2003. Oxford: Update Software.
- 7 Verdugo RJ, Salinas RS, Castillo J, Cea JG. Surgical versus non-surgical treatment for carpal tunnel syndrome (Cochrane Review). In: *The Cochrane Library*, Issue 1, 2003. Oxford: Update Software.
- 8 Gerritsen AA, de Vet HC, Scholten RJ, Bertelsmann FW *et al*. Splinting vs surgery in the treatment of carpal tunnel syndrome: a randomised controlled trial. *JAMA* 2002;288:1245–51.