

Nasal carcinoma – a rare indication for a permanent pacemaker

Simon Campbell, David Walker, Sandro Lanzon-Miller and Paul Gurr

ABSTRACT – Cardiac sinus syncope is a recognised but rare complication of head and neck cancers. Although electrical pacing remains an important treatment to prevent further syncopal episodes related to bradycardia, vasopressor-related syncope remains a more difficult management problem. The article describes the case of a 66-year-old patient with metastatic squamous cell carcinoma of the nose, who presented with syncope and exhibited carotid sinus syncope related to both carotid body invasion and vasopressor mechanisms. Successful management by the insertion of a permanent pacemaker is described, and a review of the literature on this rare complication is given.

KEY WORDS: carotid sinus syncope, pacemaker, squamous cell carcinoma, vasopressor related syncope

Metastatic malignant disease of the head and neck is a recognised but rare cause of carotid sinus syncope. The mechanisms underlying carotid sinus syncope are complex. Recognising the symptoms and signs of the different types of carotid sinus syncope are essential if it is to be managed successfully.

Patient history

A 66-year-old man presented in November 1998 with a large 2-cm ulcerating lesion arising from his right nasal vestibule. He had first noticed it one month before and it had rapidly grown since then. The lesion extended from the right nasal vestibule to the floor of the nostril. We found no enlarged lymph glands in the neck. A biopsy of the lesion showed a well differentiated squamous cell carcinoma. A magnetic resonance imaging (MRI) scan of the head and neck was otherwise normal, staging the disease as T3 N0. In view of the difficult location, the patient underwent radiotherapy with a three-field arrangement with a wax block to bolus up the nose and nasal cavity. A dose of 55 Gy in 20 fractions was given over four weeks. After two months, there was no visible tumour at the nostril, and clinical examination at that stage was normal.

In May 2001, a right submandibular lymph node was noted. Aspiration of this site revealed metastatic disease, and a 3 cm by 2 cm necrotic lesion was confirmed on repeat MRI scan. The patient underwent a right modified neck dissection; of 17 nodes that were removed only one was positive (20 mm node with extracapsular spread). Adjunct radiotherapy was given to the area: 60 Gy to the right neck and 50 Gy to the left neck. He made a good post-operative recovery.

The patient presented in December 2001 to casualty after a syncopal episode. There were no preceding symptoms. Localised cutaneous radiotherapy changes affecting the right neck, a right palatal palsy and right vocal cord palsy suggested a right vagal nerve palsy. There was no palpable lymphadenopathy. Routine X-ray and laboratory investigations were also normal. While being monitored in hospital, he had another witnessed syncopal episode associated with profound sinus bradycardia (pulse 38 b/min, blood pressure 60/40) (see Fig 1a). This rapidly responded to a bolus of 1 mg intravenous atropine. A temporary pacing wire was inserted (Fig 1b). Over the next five days, the pacemaker paced only once for five seconds. Despite this, the patient had two brief episodes of syncope associated with hypotension (but no bradycardia or pacing), suggesting vasopressor manifestations. These resolved spontaneously without therapeutic intervention. The pacemaker was switched off and the patient was observed with electrocardiographic monitoring. Within one hour, he had a further bradycardic syncopal episode which needed another

Simon Campbell
MRCP(UK) MD(Edin),
Specialist Registrar,
Royal Berkshire
Hospital, Reading

David Walker MB
ChB, Senior House
Officer, Northern
General Hospital,
Sheffield

Sandro Lanzon-Miller FRCP(UK),
Consultant
Physician*

Paul Gurr FRCS,
Consultant
Surgeon*

*Milton Keynes
General Hospital

Clin Med
2004;4:165–7

Key Points

Pacemaker insertion is an effective therapy for carotid sinus syncope associated with carotid body invasion.

It is important to be aware of the possible presence of vasopressor-related syncope because it does not usually respond to electrical pacing and may require alternative therapeutic strategies.

As in this case, vasopressor symptoms may be short lived after pacing and may resolve spontaneously as other adaptive mechanisms come into play.

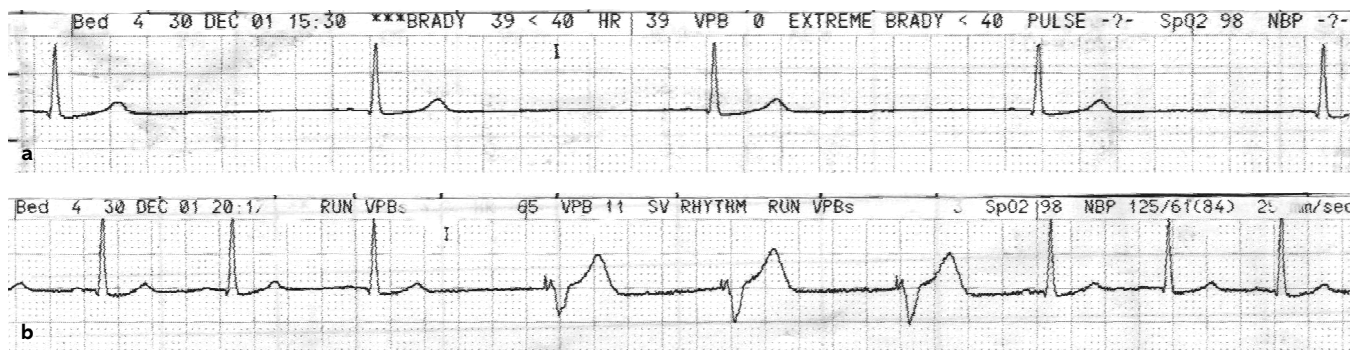


Fig 1. Electrocardiogram traces of (a) patient with profound sinus bradycardia associated with syncope; (b) same patient after temporary pacing wire insertion.

bolus of 1 mg atropine to control it. The patient was referred for a permanent pacemaker. A dual chamber sensing, dual chamber pacing, dual chamber responding and rate modulated (DDDR) pacemaker (Sorin Biomedics, USA) was inserted and he remains asymptomatic to date. A computed tomography (CT) scan of the head and neck confirmed recurrent metastatic disease, with malignant invasion into the carotid body and vagus nerve (Fig 2). He is currently undergoing further localised radiotherapy to the right neck and remains free from syncopal episodes three months later.

Discussion

The main function of the carotid body is regulation of heart rate and blood pressure. Baroreceptors in the wall of the carotid sinus and the arch of the aorta regulate this. The carotid sinus reflex is initiated by receptors and myelinated fibres in the tunica adventitia (forming the carotid sinus nerve of Hering) which then run between the internal and external carotid arteries. These fibres join the glossopharyngeal nerve with smaller branches to the hypoglossal, vagus and cervical sympathetic nerves to the vasomotor and cardioinhibitory areas of the reticular formation of the medulla. The efferent nerves descend into the cervical sympathetic nerves and the vagus nerve.

Carotid sinus stimulation gives rise to three types of cardioinhibitory responses:¹

- type 1, as described here, resulting in bradycardia and/or hypotension (typically responding to atropine)
- type 2, or vasopressive response, resulting in vasodilatation and hypotension (responding to ephedrine)
- type 3, a primarily cerebral response not associated with bradycardia or hypotension (related to cerebral blood flow insufficiency during carotid stimulation).²

The most common variety is type 1, which accounts for up to 70% of cases, with type 2 and type 3 accounting for the remainder.

The presence of a hyperreactive carotid sinus is diagnostic if syncopal symptoms are reproduced by carotid sinus massage. This certainly happened in our patient. Carotid sinus syncope has been documented only a few times in the literature in

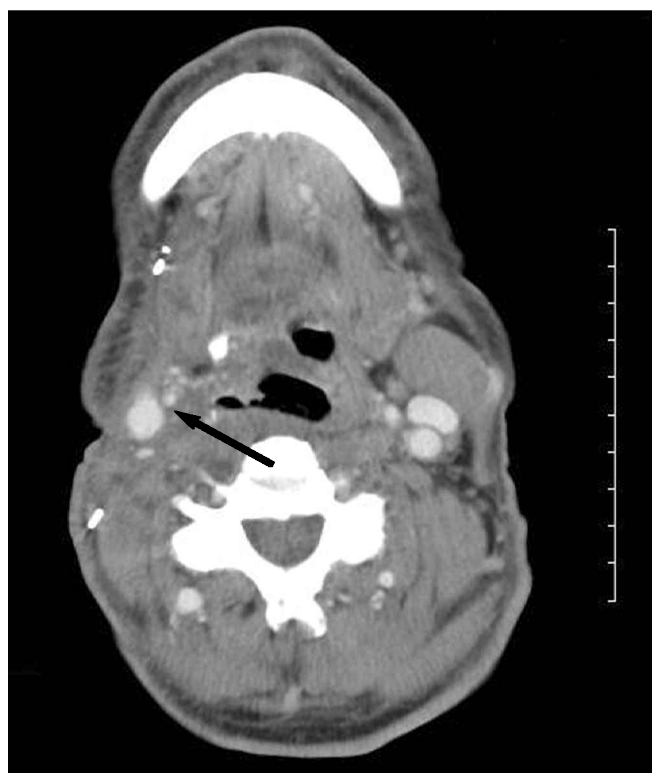


Fig 2. CT scan at the level of the carotid body, showing signs of malignant invasion into the right vagus nerve and right carotid body (arrow).

patients with head and neck malignancy.³⁻⁶ This has been in association with carotid body tumours, inflammatory masses and enlarged lymph nodes. Voss and Magnin described the first patient to be successfully treated with a demand pacemaker in 1970;⁷ this has been subsequently described in the literature.⁸⁻¹² This parallels our initial management with use of a ventricular demand temporary pacemaker. While pacemaker insertion appears to be an effective therapy for type 1 carotid sinus stimulation, the management of vasopressor manifestations (type 2) may require different treatment. Ephedrine is effective in the short term but, as in our patient, may resolve spontaneously

soon after pacemaker insertion.⁹ The exact reasons for this remain unclear, and therapy with ephedrine was not possible in this patient due to the brief nature of his syncopal episodes. It may be that other adaptive mechanisms come into play, making type 2 carotid sinus stimulation a short-lived event after pacemaker insertion. Our patient exhibited both type 1 and type 2 forms of carotid sinus stimulation, with the latter being revealed only after temporary (ventricular) electrical pacing. Mixed cardioinhibitory carotid sinus stimulation has been documented only once before.¹³ The later use of a dual chamber (rate responsive) pacemaker with a rate drop algorithm may also have accounted for the patient's subsequent successful management.

References

- 1 Weiss S, Baker JP. The carotid sinus reflex in health and disease: its role in the causation of fainting and convulsions. *Medicine* 1933;**12**: 297–354.
- 2 Gurdijan ES, Webster JE, Hardy WG. Nonexistence of the so-called cerebral form of carotid sinus syncope. *Neurology* 1958;**8**:818–26.
- 3 Ballantyne F, VanderArk CR, Hilick M. Carotid sinus syncope and cervical lymphoma. *Wisconsin Med J* 1975;**74**(8):91–2.
- 4 Dickinson JM, Traver CA. Carotid body tumours: review of the literature with report of two cases. *Am J Surg* 1945;**69**:9–16.
- 5 Lapiorey G, Grand A. [Carotid adenopathy with hyper-reflectivity syndrome of the carotid sinus. Surgical problems.] (French). *J Fr Oto-Rhino Laryngol Audiophonol Chirurg Maxillo-Faciale* 1973;**22**(1):19–29.
- 6 Roger J, Vigouroux RA, Gouin M, Regis H, Bremond G. [Multiple syncopes. Compressive adenopathy of the carotid sinus externalized 3 years after clinical onset: surgical recovery.] (French). *Marseille Med* 1969;**106**(4):333–5.
- 7 Voss DM, Magnin GE. Demand pacing and carotid sinus syncope. *Am Heart J* 1970;**79**(4):544–7.
- 8 Cicogna R, Curnis A, Dei CL, Visioli O. Syncope and tumours in the neck: carotid sinus or glossopharyngeal syndrome? *Eur Heart J* 1985;**6**(11):979–84.
- 9 Patel AK, Yap VU, Fields J, Thomsen JH. Carotid sinus syncope induced by malignant tumors in the neck. Emergence of vasodepressor manifestations following pacemaker therapy. *Arch Intern Med* 1979;**139**(11): 1281–4.
- 10 Peretz DI, Abdulla A. Management of cardioinhibitory hypersensitive carotid sinus syncope with permanent cardiac pacing – a seventeen year prospective study. *Can J Cardiol* 1985;**1**(2):86–91.
- 11 Strauer BE, Brunner L, Dehne N. [Treatment of carotid sinus syndrome with cardiac pacemaker stimulation.] (German). *Deutsche Med Wochenschrift* 1973;**98**(11):558–60.
- 12 Von Maur K, Nelson EW, Holsinger JW, Eliot RS. Hypersensitive carotid sinus syncope treated by implantable demand cardiac pacemaker. *Am J Cardiol* 1972;**29**(1):109–10.
- 13 Walter PF, Crawley IS, Dorney ER. Carotid sinus hypersensitivity and syncope. *Am J Cardiol* 1978;**42**(3):396–403.