

## PET and SPECT in common neuropsychiatric disease

**Klaus Tatsch** MD, Associate Professor of Nuclear Medicine, *University of Munich-Grosshadern, Munich, Germany*

**Peter J Ell** FMedSci, University Chair and Director of Institute of Nuclear Medicine, *UCL; Clinical Director, University College London Hospitals NHS Trust, London*

*Clin Med* 2006;**6**:259–62

This article addresses the increased interest of nuclear medicine applications in common neuropsychiatric disorders: extrapyramidal pathology, the dementias and brain tumours.

### Extrapyramidal diseases

The most relevant extrapyramidal diseases are Parkinson's disease (PD) and atypical parkinsonian syndromes such as multiple system atrophy (MSA), progressive supranuclear palsy (PSP) and corticobasal degeneration (CBD). In all these, establishment of an early and accurate diagnosis impacts on management, helps to avoid inappropriate treatment and assists in the evaluation of novel drugs.

Pathology in extrapyramidal diseases involves the dopaminergic neurotransmitter system, so positron emission tomography (PET) and single-photon emission computed tomography (SPECT) investigations contribute significantly to establishing the correct diagnosis.<sup>1–3</sup> Presynaptic nigrostriatal terminal function can be assessed with radioligands suitable for imaging:

- aromatic amino acid decarboxylase activity (PET: fluorodopa)
- vesicular monoamine transporter type 2 (PET: dihydrotetrabenazine)
- plasma membrane dopamine transporter (PET and SPECT: cocaine analogues).

Imaging of postsynaptic dopamine receptors has focused on the D2-like receptor system (PET: raclopride, (desmethoxy) fallypride; SPECT: iodobenzamide, iodobenzofuran, epidepride).

There are two major clinical indications for these techniques:

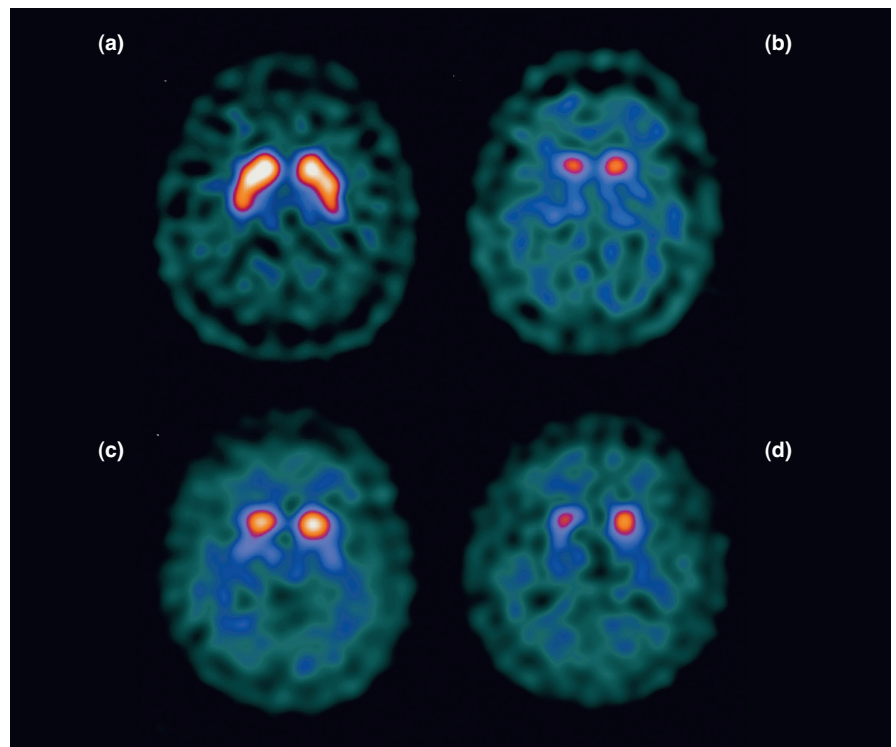
- confirmation or exclusion of neurodegenerative parkinsonism
- the differential diagnosis between PD and atypical parkinsonian syndromes.

### Neurodegenerative parkinsonism

An important question is whether patients with equivocal or unclear symptoms suffer from a nigrostriatal deficit (eg neurodegenerative parkinsonian syndromes) or from diseases not associated with dopamine terminal dysfunction but which may mimic 'true' parkinsonism. In this situation, PET and SPECT imaging allows confirmation or exclusion of a presynaptic dopaminergic

deficit. Patients with PD and atypical parkinsonism can be clearly distinguished from healthy controls, patients with drug-induced or psychogenic parkinsonism, those with essential tremor and other tremor syndromes and patients with dopa-responsive dystonia (Fig 1). Dopamine terminals are not involved in the latter groups and normal presynaptic findings have been reported.<sup>1,2</sup>

Presynaptic terminal function is compromised in all neurodegenerative parkinsonian syndromes so this parameter does not contribute significantly to the differential diagnosis of these syndromes, particularly not between PD and atypical parkinsonism. This is rather the domain of postsynaptic D2 receptor imaging, the diagnostic accuracy of which is about 80–90%. Postsynaptically located D2 receptors are primarily not compromised in PD, so D2 receptor binding has been shown to be normal or even increased in untreated patients (Fig 2(a)).



**Fig 1. Presynaptic dopamine transporter imaging with single-photon emission computed tomography ( $^{123}\text{I}$ -FP-CIT) to distinguish between disease with and without nigrostriatal deficit: (a) illnesses without involvement of presynaptic terminals (eg essential tremor) show normal findings but neurodegenerative parkinsonian syndromes such as (b) Parkinson's disease, (c) multiple system atrophy and (d) progressive supranuclear palsy are characterised by clearly compromised binding to the presynaptic dopamine transporter.**

The increase has been attributed to receptor upregulation as compensation for the presynaptic deficit.

## Atypical parkinsonian syndromes

In contrast, neurodegeneration affects both pre- and postsynaptic nerve fibres in atypical parkinsonian syndromes. Neurodegeneration in postsynaptic nerve fibres is reflected in reduced striatal D2 receptor binding (Fig 2(b)) – corresponding well with the receptor loss reported in post-mortem investigations. Based on D2 receptor studies, however, distinction among MSA, PSP and CBD is barely possible.<sup>1-3</sup>

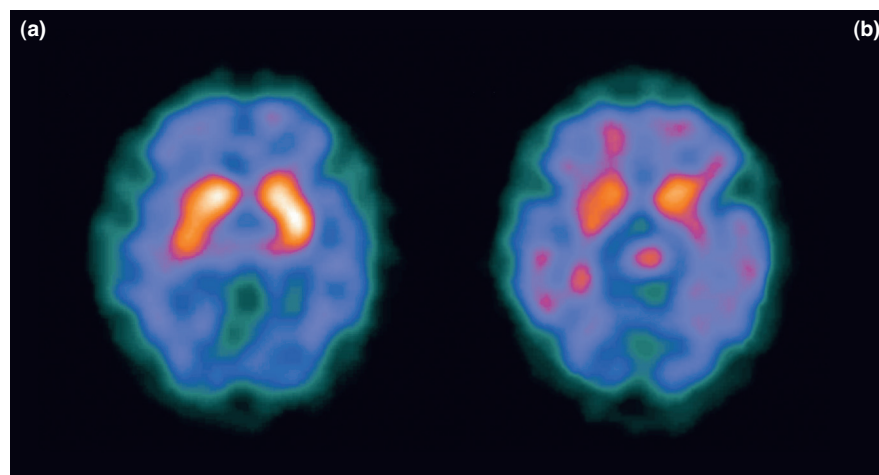
## Dementias

Dementias are widespread and their prevalence continues to grow with increased human life expectancy. The most common cause is Alzheimer's disease (AD), accounting for 60–70% of all dementias in the elderly, followed by Lewy body dementia (LBD) (10–25%), vascular dementia (10–15%) and frontotemporal dementia (FTD) (5–10%). Synaptic dysfunction or loss – a hallmark of different types of dementia – entails at the molecular level several mechanisms that finally result in decreased energy demand. Therefore, assessment of glucose metabolism with 18F-fluorodeoxyglucose (FDG) PET is a valid tool for imaging the energy metabolism of the brain and its typical changes in dementia.<sup>4,5</sup> Regional cerebral blood flow (rCBF) is closely coupled to glucose metabolism and rCBF studies have also been widely used in dementia.<sup>6,7</sup>

Compared with these techniques, assessment of specific neurotransmitter systems (eg the cholinergic system) has to date gained less clinical significance. The more recently introduced tracers that directly target amyloid plaques and neurofibrillary tangles require further evaluation before their clinical application will be feasible.

## Alzheimer's disease

Brain imaging with PET and SPECT allows the identification of regional pat-



**Fig 2. Postsynaptic dopamine D2 receptor imaging with single-photon emission computed tomography (iodobenzamide) to distinguish between Parkinson's disease (PD) and atypical parkinsonian syndromes: (a) PD patients present with normal or increased D2 receptor binding (here in the left posterior putamen), suggesting preserved or upregulated postsynaptic receptors, whereas (b) in atypical parkinsonian syndromes (eg multiple system atrophy) D2 receptor binding is reduced, reflecting degeneration of postsynaptic receptor binding sites.**

terns of metabolism and perfusion associated with the major types of dementia (Fig 3). In AD patients the most commonly observed pattern is a bilateral, more or less symmetrical, temporoparietal deficit which extends in more severe stages to the frontal cortex.<sup>4-7</sup> Typically, the primary sensorimotor cortex, basal ganglia, thalamus and cerebellum are spared (Fig 3(a)). In incipient AD, abnormalities are first observed in the medial temporal cortex, the posterior cingulate and the precuneus. Even earlier, at a preclinical stage, patients with mild cognitive impairment have presented with specific changes predictive of later conversion to AD. In general, the magnitude of deficits in imaging studies correlates well with the degree of cognitive impairment. FDG PET has been considered to provide slightly more accurate results than rCBF SPECT studies.<sup>6,7</sup> The diagnostic power of both has been further enhanced by the application of newer analytical techniques such as voxel-based and discriminant function analyses.<sup>6</sup>

## Lewy body dementia

In LBD, cognitive decline is often accompanied by visual hallucinations and gait or parkinsonian symptoms. In addition

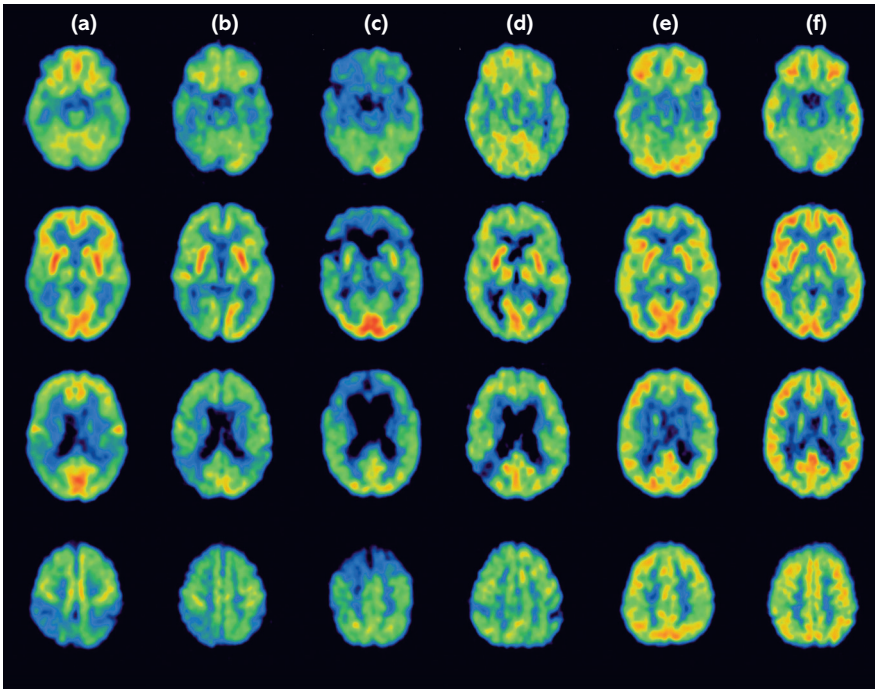
to temporoparietal deficits (which may appear similar to the pattern in AD), LBD patients present with occipital hypometabolism and hypoperfusion (Fig 3(b)). Assessment of the presynaptic dopaminergic system may be of more value than in AD as there is growing evidence that LBD (unlike AD) is associated with a presynaptic dopaminergic deficit (as in PD).<sup>4-7</sup>

## Frontotemporal dementia

FTD comprises a group of dementias, including Pick's disease, clinically characterised by behavioural and language disturbances accompanied by or which even precede memory deficits. It may be difficult to distinguish from AD on the basis of symptomatology alone. Scans characteristically show metabolic and perfusion deficits in the frontal, anterior temporal and medial temporal cortices (Fig 3(c)).<sup>4-7</sup>

## Vascular dementia

The diagnosis of vascular dementia, which is not a neurodegenerative dementia, is usually based upon a combination of history, neurological examination and typical magnetic resonance imaging (MRI) findings. PET and



**Fig 3.** 18F-fluorodeoxyglucose positron emission tomography scans illustrating metabolic patterns which allow differentiation both of various types of dementia and of other illnesses associated with cognitive impairment: (a) in Alzheimer's disease, metabolism is predominantly impaired in the neocortical association areas (posterior cingulate, temporoparietal and frontal cortex); (b) Lewy body dementia presents with a similar pattern but with additional occipital involvement, whereas (c) in frontotemporal dementia impairment is primarily located in the frontotemporal cortex and (d) vascular dementia presents with asymmetrical, irregularly distributed deficits. These patterns are easily distinguishable from those in (e) major depression and in (f) healthy controls. The pattern in major depression does not differ markedly from that in controls except for possibly slightly reduced metabolism in the frontal cortex.

SPECT investigation, which are restricted to equivocal cases, typically show deficits in the border zone areas of the middle cerebral artery territory or at the end-point of the posterior cerebral artery, giving an asymmetrical patchy imaging pattern (Fig 3(d)).<sup>4-7</sup>

In addition to differential diagnosis among the dementias, it is important to distinguish dementias from other illnesses associated with cognitive impairment, such as 'pseudodementia' in depression. In the latter situation, PET and SPECT images demonstrate comparatively normal findings clearly different from the patterns described above (Fig 3(e)).

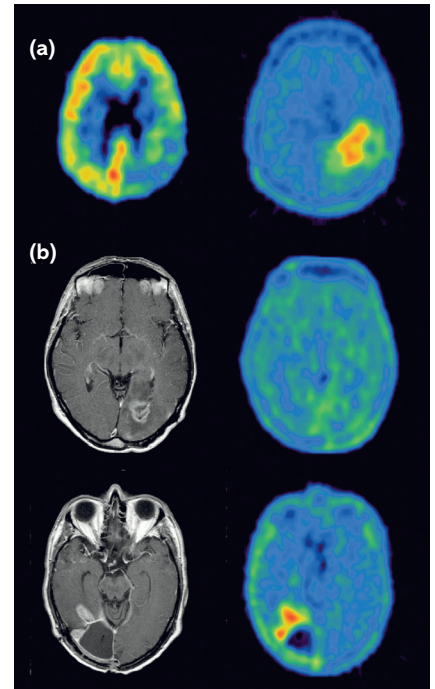
### Brain tumours

Novel systemic and locoregional treatments for glioma require precise assessment of the pretherapeutic status as well

as correct classification of therapy-induced reactive changes. Functional imaging techniques have successfully met this challenge. The main functions studied in the routine setting are glucose metabolism (FDG) and amino acid transport (PET: methionine, fluoroethyl-tyrosine; SPECT: iodomethyltyrosine).<sup>8-10</sup> High resolution is a basic requirement for imaging gliomas so PET should be preferred over SPECT.

### Tumour detection

For tumour detection, amino acid tracers may be superior to FDG since most low- and high-grade gliomas present with markedly elevated amino acid uptake, mainly related to increased transport rate based on elevated expression of the respective membrane transporters. FDG also identifies high-grade gliomas on the basis of their elevated glucose consump-



**Fig 4.** Positron emission tomography (PET) scans in a patient with glioblastoma: (a) (left) 18F-fluorodeoxyglucose and (right) amino acid; amino acid provides a considerably higher tumour to target ratio, allowing easier detection and delineation of the tumour borders; (b) differential diagnoses between tumour recurrence and therapy-induced benign changes. Both cases present with contrast-enhancing lesions on magnetic resonance imaging scans that are suspicious for recurrence, but the amino acid PET scan is negative in the first example (upper row). As confirmed by biopsy, this patient was tumour free; histopathology revealed only reactive changes following radiation therapy. Increased amino acid uptake clearly indicated recurrent glioma in the other case (lower row).

tion (Fig 4(a)). Because of the physiologically high cortical uptake, however, it may be difficult to detect both small lesions and also low-grade gliomas which usually present with FDG uptake close to that of normal white matter.<sup>8,9</sup>

### Determination of tumour borders

Beyond tumour detection, precise determination of tumour borders is mandatory for optimal treatment planning. FDG may be less suitable for this purpose since high cortical uptake and low



tumour/background contrast can hamper clear definition of tumour boundaries. In contrast, amino acid tracers have been proven accurately to identify the solid parts of brain tumours as well as the area of infiltration, thereby allowing distinction between glioma tissue and peritumoural tissue.

## Tumour grading

Glucose uptake correlates well with the histological tumour grade, so FDG PET is a valuable tool for accurate differentiation of low- and high-grade gliomas. Furthermore, in biopsy-proven low-grade gliomas, tumoural FDG uptake correlates well with the risk of malignant transformation.<sup>8,9</sup> The role of amino acid tracers in tumour grading is more controversial since standard evaluations reveal a marked overlap between tumour classifications. More recently, however, analysis of tracer uptake kinetics has been suggested as a clue to tumour grading since there is evidence that low- and high-grade gliomas have different kinetic behaviour.<sup>10</sup>

## Prognosis

Both FDG and amino acid tracers provide useful information regarding prognosis. Several studies show that FDG uptake in gliomas is well correlated with survival. It has recently been claimed that FDG PET outperforms pathological grading in determining prognosis in glioma patients. Studies with amino acid tracers also provide prognostic information independent of tumour grading. This technique has been confirmed as an important prognostic indicator for patients with low- and high-grade glioma in the untreated and pretreated state.<sup>8-10</sup>

## Biopsy

Because of the heterogeneous presentation of brain tumours, computed tomography- or MRI-guided stereotactic biopsy does not always depict the metabolically most active part of the tumour. In comparison, FDG PET-guided biopsies show an improved diagnostic yield

## Key Points

**Nuclear medicine excels in the differential diagnosis of movement disorders**

**Nuclear medicine aids in the differential diagnosis of dementias**

**Nuclear medicine can aid in the staging of primary brain tumours**

**Nuclear medicine participates in the assessment of therapy response of the above**

**KEY WORDS:** movement disorders, nuclear medicine, positron emission tomography, single-photon emission computed tomography

by sampling from areas expressing the highest FDG uptake. Amino acid tracers are at least equally helpful in determining the optimal biopsy site and have been proposed as a valid alternative to FDG for target selection.<sup>8,9</sup>

## Differentiation of recurrent glioma and radiation necrosis

FDG PET has been considered the (non-invasive) gold standard for the differential diagnosis of recurrent glioma and radiation necrosis. Its value has been questioned recently because of a considerable number of false-positive results following high-dose radiation therapy, radiosurgery or other locoregional approaches. Findings with amino acid tracers are not compromised in this way and their power accurately to distinguish tumour recurrence and therapy-induced benign changes has been impressively documented (Fig 4(b)). This technique may offer added value.<sup>10</sup>

with clinical evaluations lacking nuclear imaging. Review. *J Nucl Med* 2004;45: 594-607.

- 5 Herholz K. PET studies in dementia. Review. *Ann Nucl Med* 2003;17:79-89.
- 6 Devous MD Sr. Functional brain imaging in the dementias: role in early detection, differential diagnosis, and longitudinal studies. Review. *Eur J Nucl Med Mol Imaging* 2002; 29:1685-96.
- 7 Van Heertum RL, Tikofsky RS. Positron emission tomography and single-photon emission computed tomography brain imaging in the evaluation of dementia. Review. *Semin Nucl Med* 2003;33:77-85.
- 8 Schaller B. Usefulness of positron emission tomography in diagnosis and treatment follow-up of brain tumors. Review. *Neurobiol Dis* 2004;15:437-48.
- 9 Spence AM, Mankoff DA, Muzi M. Positron emission tomography imaging of brain tumors. Review. *Neuroimaging Clin N Am* 2003;13:717-39.
- 10 Popperl G, Tatsch K. Imaging of gliomas: PET. *Neurosci Imaging* 2006. In press.

## References

- 1 Booij J, Tissingh G, Winogrodzka A, van Royen EA. Imaging of the dopaminergic neurotransmission system using single-photon emission tomography and positron emission tomography in patients with parkinsonism. Review. *Eur J Nucl Med* 1999; 26:171-82.
- 2 Tatsch K. Imaging of the dopaminergic system in parkinsonism with SPECT. Review. *Nucl Med Commun* 2001;22: 819-27.
- 3 Piccini P, Whone A. Functional brain imaging in the differential diagnosis of Parkinson's disease. Review. *Lancet Neurol* 2004;3:284-90.
- 4 Silverman DH. Brain 18F-FDG PET in the diagnosis of neurodegenerative dementias: comparison with perfusion SPECT and