11 Heidary N, Naik H, Burgin S. Chemotherapeutic agents and the skin: an update. *J Am Acad Dermatol* 2008;58:545–70.
12 Robert C, Soria JC, Spatz A *et al.* Cutaneous side-effects of kinase inhibitors and blocking antibodies. *Lancet Oncol* 2005;6:491–500.
13 Agero AL, Dusza SW, Benvenuto-Andrade C *et al.* Dermatologic side effects associated with the epidermal growth factor receptor inhibitors. *J Am Acad Dermatol* 2006;55:657–70.
14 Hu JC, Sadeghi P, Pinter-Brown LC, Yashar S, Chiu MW. Cutaneous side effects of epidermal growth factor receptor inhibitors: clinical presentation, pathogenesis, and management. *J Am Acad Dermatol* 2007;56:317–26.

Address for correspondence: Dr E Topham, Brighton and Sussex University Hospitals NHS Trust, Brighton General Hospital, Elm Grove, Brighton BN2 3EW. Email: emma.topham@bsuh.nhs.uk

The skin in general medicine

Sasha Dhoat, *Locum Consultant Dermatologist;* **Malcolm Rustin,** *Consultant Dermatologist*
Royal Free Hospital, London

KEY WORDS: skin, lyme disease, Kawasaki disease, hand, foot and mouth disease

Cutaneous manifestations of systemic disorders are common in general medicine and can be important presenting features of internal disease.[1,2] This review is not comprehensive but highlights the most frequent and important entities.

Infections

Lyme disease (or borreliosis)

The most common tick-borne disease in the northern hemisphere is lyme disease. It is transmitted to humans through the bite of an ixodes tick infected with spirochetes *Borrelia afzelii* or *Borrelia garinii* (most commonly in Europe) or *Borrelia burgdorfei* (in the USA). Cases of lyme disease confirmed by UK laboratories have increased tenfold since records began in 1986. Several hundred cases are reported every year, mainly in the south-western regions of the country during summer months. The disease develops in three stages:

- *1st stage*: in 50–75% of patients the classical rash of erythema chronicum migrans occurs up to four weeks after the tick bite (Fig 1). The annular erythema gradually spreads outwards from the site of the bite; it is usually at least 5 cm in diameter and may develop central clearing, bruising or necrosis.
- *2nd stage*: this may be followed by lesions of multiple secondary erythema migrans, musculoskeletal symptoms (60%) (often migratory joint pain with or without joint swelling), neurological manifestations (15%) (meningitis, facial cranial nerve paralysis and radicular neuropathies) or, less commonly, cardiovascular complications (8%), including varying degrees of atrioventricular block).
- *3rd stage*: in 60% of untreated cases the next stage begins at least seven months after the primary infection. It can manifest as intermittent pain and swelling of the knees and hips, which may progress to chronic arthritis (10%). Occasionally, polyneuropathy or encephalopathy may develop.

Diagnosis and treatment. The history of a tick bite and skin eruption is highly characteristic and the diagnosis is primarily clinical.[3] Serological testing (ELISA and Western blot) is sensitive, but not specific; both tests may be negative early in the disease and they do not accurately distinguish active from past infection. Lyme disease can be confirmed only by culture, although this is a low yield procedure. Treatment with doxycycline 200 mg od for one month should be initiated early to prevent complications.

Tuberculides

Tuberculides are cutaneous hypersensitivity reactions to tuberculosis (TB)

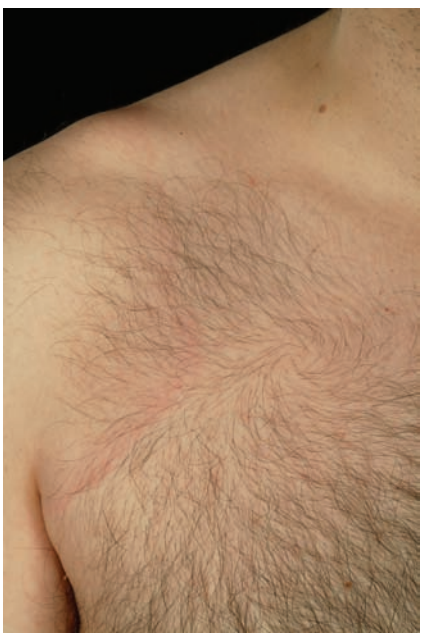

Fig 1. Erythema chronicum migrans.

elsewhere in the body.[4,5] Immunity is usually high, leading to destruction of bacilli which are therefore not usually demonstrable on skin lesions.

Erythema induratum

Erythema induratum presents as red, painful warm nodules on the lower limbs, often associated with fever and joint pains. Unlike erythema nodosum, lesions may ulcerate and they do not resolve spontaneously. Although no overt focus of TB may be found, the Mantoux and ELISpot tests are strongly positive and the skin changes usually respond to antituberculous therapy. Histology is characterised by a lobular panniculitis and vasculitis.

Scrofuloderma

Scrofuloderma results from breakdown of skin overlying a tuberculous focus, usually at a lymph node. It presents as firm, painless, subcutaneous nodules that gradually enlarge and suppurate forming ulcers and sinus tracts in overlying skin. Tubercle bacilli can usually be isolated from the purulent discharge.

Lupus vulgaris

Lupus vulgaris, the most common form of cutaneous TB, presents as a solitary reddish-brown plaque, often on the face, which shows an 'apple-jelly' colour when pressed with a glass spatula (diascopy). Lesions occur due to direct extension of underlying tuberculous foci, lymphatic or haematogenous spread, after primary inoculation, BCG vaccination or in scars of old scrofuloderma. Affected individuals have a moderate or high degree of immunity and so isolation of acid-fast bacilli is rare.

Bacillary angiomatosis

Bacillary angiomatosis presents as multiple angiomas, primarily in patients with AIDS, due to bacteria of the Bartonella genus. *Bartonella henselae* is most often transmitted through a cat scratch or bite but also by ticks and fleas. *Bartonella quintana* is usually transmitted by lice.

Kawasaki disease

The most common vasculitic disorder of childhood worldwide is Kawasaki disease. It is the leading cause of acquired heart disease among children in developed countries. It presents with high spiking fever lasting at least five days and at least five of the following six symptoms (Fig 2):

- bilateral conjunctivitis
- red, dry cracked lips
- red oral and pharyngeal mucosa
- strawberry tongue
- widespread polymorphous rash
- red swollen hands and, later, desquamation of the fingers, toes, palms and soles.

Up to one-fifth of untreated children develop coronary artery aneurysms which can be associated with mortality. Early recognition of this syndrome allows initiation of high-dose intravenous (iv) immunoglobulin (Ig) (2 gm/kg single dose) and aspirin (75–80 mg/kg/day initially, followed by aspirin 3–5 mg/kg/day in the convalescent phase). This is essential to prevent cardiovascular complications.

Hand, foot and mouth disease

A disease of childhood, hand, foot and mouth disease, is caused by infection

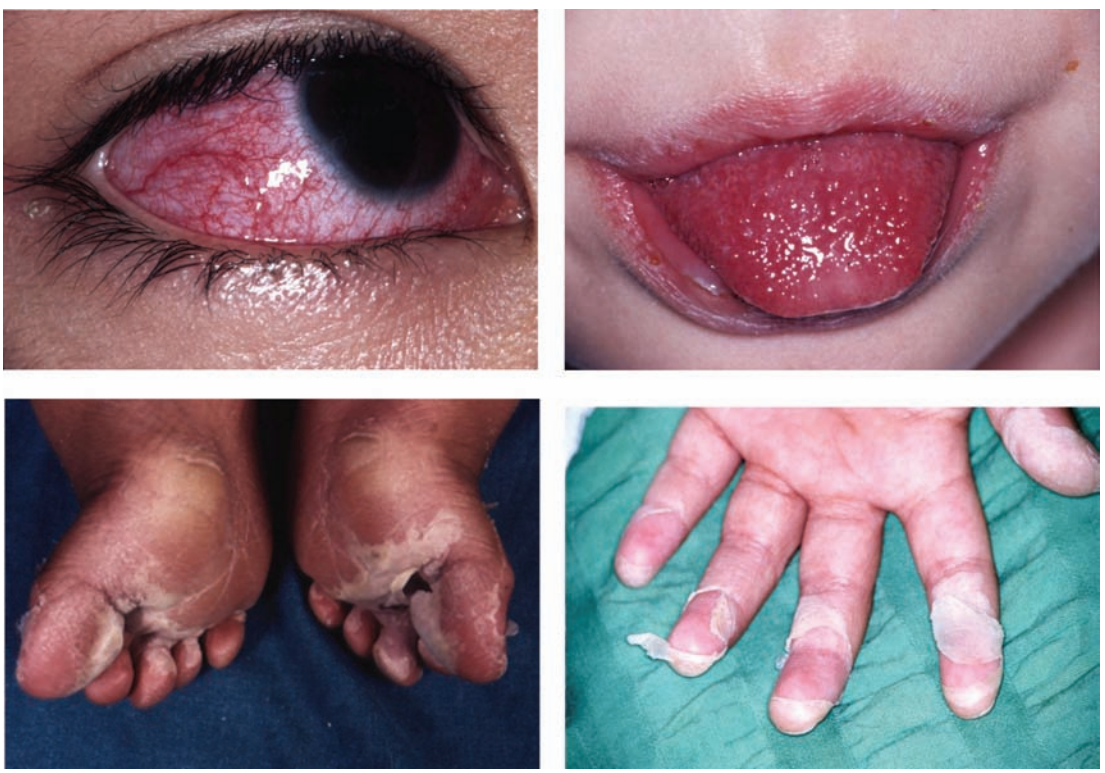

Fig 2. Manifestations of Kawasaki disease.

with non-polio enteroviruses, such as coxsackie virus A16 and enterovirus 71. It is transmitted via contact with infected saliva and fluid from blisters or stool. After an incubation period of 3–7 days, oval vesicles with a slightly grey centre develop in the mouth and on the hands and feet. Fever, malaise, sore throat, vomiting and/or diarrhoea may occur.

Symptoms usually resolve within 10 days and more than two-thirds of infected cases remain asymptomatic. Polymerase chain reaction can be used to identify enterovirus 71 which may cause severe neurological disease (including viral meningitis, encephalitis or acute flaccid paralysis), as well as pulmonary oedema/haemorrhage and myocarditis. Treatment is supportive.

Gastrointestinal disease

Inflammatory bowel disease

Erythema nodosum may be associated with inflammatory bowel disease. There are crops of acute tender, red smooth nodules, usually over the extensor surfaces of the shins, possibly accompanied by mild fever, malaise and joint pains. Lesions may reach a diameter of 3–4 cm. Later they become mauve and last one to two weeks. It often reflects active bowel disease but may precede it. The whole episode may resolve within six weeks.

Other associations include:

- pyoderma gangrenosum (which may not reflect bowel disease activity)
- urticaria
- vasculitis (small vessel type and cutaneous polyarteritis nodosa)
- oral lesions, including ulcers, angular stomatitis, pyostomatitis vegetans (a mucosal variant of pyoderma gangrenosum), granulomatous infiltrates of the lips (only Crohn's disease) and acquired enteropathica-like lesions.

Acrodermatitis enteropathica

Associated with zinc deficiency is acrodermatitis enteropathica, a triad of circumorificial and acral dermatitis, alopecia and diarrhoea. It is an autosomal recessive disorder which presents within a few days or weeks of life. The vesiculobullous lesions, which crust and erode, occur around the eyes, mouth, ears, nose, anus and genitalia, and on the fingers and toes.

A similar eruption can be seen with inadequate zinc intake due to anorexia nervosa, vegetarian diets or parenteral nutrition, and with reduced zinc absorption in coeliac disease, pancreatic insufficiency, cystic fibrosis, severe infantile diarrhoea and alcoholism.

Dermatitis herpetiformis[6]

This is an extremely itchy, vesiculopapular eruption, usually associated with gluten-sensitive enteropathy. Grouped vesicles symmetrically involve the buttocks, knees, elbows and scalp (Fig 3). Urticarial lesions and excoriations due to intense pruritus are common (hence vesicles are often difficult to detect). Mucous membranes are occasionally involved.

Overt malabsorption is very rare, except in patients with associated coeliac disease, prevalence 3.7–11.1%, so intestinal biopsies are not performed in asymptomatic patients. There is a small increased risk of gastrointestinal (GI) malignancy, especially lymphoma (incidence <2%) and some evidence to suggest a protective role of a gluten-free diet (GFD).

Anti-endomysial antibodies are present in 52–100% of patients (tissue transglutaminase sensitivity 100%, specificity 80%), providing a helpful method to assess adherence to a GFD. Diagnosis is confirmed by demonstration of granular IgA deposits at the dermo-epidermal junction in perilesional or normal skin (sensitivity 92.4%).

Liver disease

Mixed cryoglobulinaemia

It is estimated that 70–90% of patients with mixed cryoglobulinaemia (circulating Igs complexed with other Igs that reversibly precipitate in the cold) have hepatitis C. A triad of palpable purpura on the lower extremities (Fig 4), glomerulonephritis (26%) and peripheral neuropathy (8%) should prompt a screen for hepatitis C infection and serum IgM and IgG cryoglobulins. Lesions usually arise after cold exposure or prolonged standing or sitting, last 3–10 days and can be associated with arthralgia (21%).

Polyarteritis nodosa

Also sometimes associated with hepatitis B and C infection is polyarteritis nodosa, a multisystem segmental necrotising

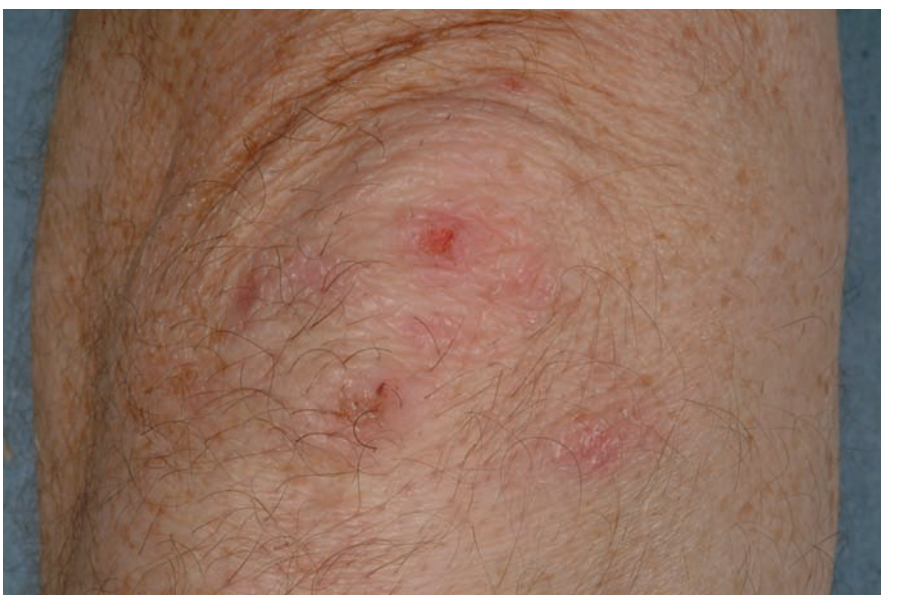

Fig 3. Excoriated papules and vesicles in dermatitis herpetiformis.

vasculitis of small and medium vessels with end-organ damage due to ischaemia, infarcts and haemorrhage. Painful nodules on the lower legs along the course of the superficial arteries, livedo reticularis, digital infarction and large ulcers may be accompanied by paraesthaesiae, renal disease, hypertension, arthralgias and myalgias. Skin or muscle/nerve biopsy may be helpful and an arteriogram demonstrates aneurysms or occlusions of the visceral arteries.

Acquired porphyria cutanea tarda

A photosensitivite disorder, acquired porphyria cutanea tarda, is caused by inhibition of the liver enzyme uroporphyrin decarboxylase, a step in the pathway of haem synthesis. Inhibitors of the enzyme are formed in the presence of iron and reactive oxygen species, such as in hepatitis C, haemochromatosis, alcohol and oestrogen intake. The resultant accumulation of uroporphyrins and coproporphyrins is hepatotoxic; it may cause liver cirrhosis and in some cases hepatocellular carcinoma.

Adults present with tense blisters on sun-exposed sites, especially the back of the hands and face, skin fragility and healing with scars and milia. There may be hypertrichosis, hyperpigmentation and morphoea. Urine and blood/faeces samples demonstrate an excess of uroporphyrins (samples must be protected from light and transported in black opaque bags).

Primary biliary cirrhosis

Primary biliary cirrhosis (PBC) is commonly associated with generalised pruritus (70%), diffuse hyperpigmentation and xanthomata (eruptive, planar and occasionally tuberous). There is also a more frequent association with lichen planus, scleroderma and CREST syndrome (calcinosis, Raynaud's phenomenon, sclerodactyly, oesophageal involvement, telangiectasia). In one series, the dermatological lesion was the presenting symptom or sign leading to the diagnosis in more than a third of patients. The diagnosis is confirmed by demonstration of M2 antimitochondrial antibodies (present in 95% patients).

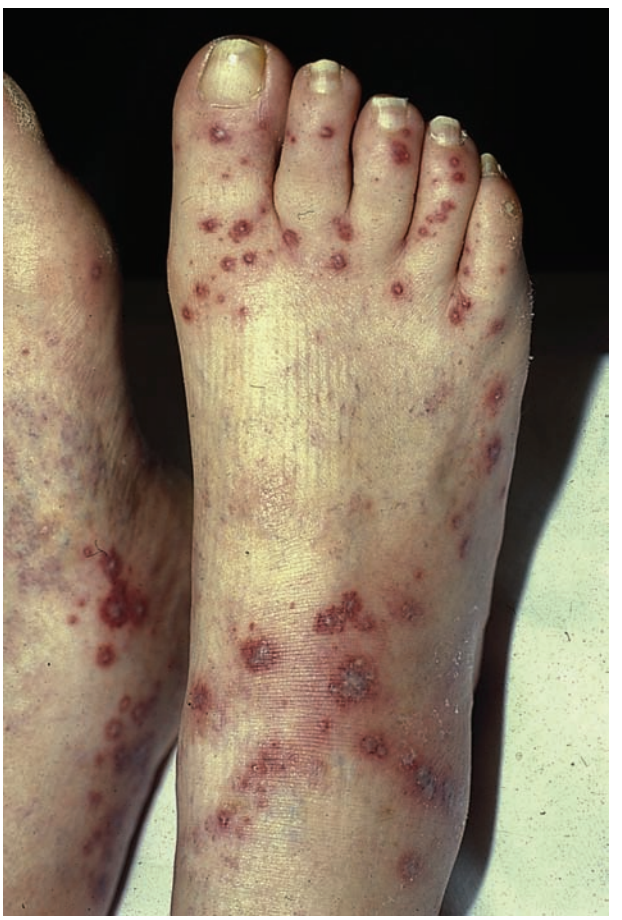

Fig 4. Vasculitic rash of mixed cryoglobulinaemia.

Endocrine disease

Pretibial myxoedema

This condition presents as red to skin coloured, purple/brown or yellowish waxy indurated plaques on the anterolateral aspect of the lower legs or feet, characteristically with a peau d'orange appearance. It may also manifest as a diffuse non-pitting oedema. There may be localised hypertrichosis and hyperhidrosis. It is due to mucin deposition, often associated with hyperthyroidism (Graves' disease patients 1.5%, exophthalmos 25%), but can appear following treatment of thyroid disease.

Hirsutism

The growth of terminal hair (hirsutism) in females in normally non-hairy sites can be racial or due to:

- increased production of ovarian androgens (polycystic ovaries, ovarian tumours)
- increased production of adrenal androgens (adrenal tumour/hyperplasia or hyperpituitarism)
- ovarian failure (postmenopausal or post-oophorectomy)
- androgenic drugs (testosterone, systemic steroids, danazol).

Acne can also be androgen driven and may coexist. Screening tests may include plasma testosterone, sex hormone binding globulin, prolactin, luteinising and follicular stimulating hormone levels, 17α-hydroxyprogesterone, dehydroepiandrosterone sulphate and androstenedione.

Metabolic disease

Fabry disease

A rare X-linked disorder of males, Fabry disease, due to a deficiency of α-galactosidase A, causes deposition of glycolipid in small blood vessels of the skin, kidneys, heart and brain. Soon after puberty, red or black telangiectatic macules and papules up to 0.5 cm in diameter arise diffusely around the umbilicus and lower trunk, over the hips, buttocks, thighs and genitalia. Angiokeratomas of the skin may occur in heterozygote female carriers who are usually asymptomatic. Periodic bouts of excruciating burning pain in the extremities associated with fever are characteristic. Diagnosis by skin biopsy is vital as replacement of the missing enzyme by iv infusion prevents life-threatening renal failure, myocardial infarction and cerebrovascular accident.

Xanthomatoses

Xanthomatoses are characterised by lipid deposition in the skin due to hyperlipidaemia either from a primary genetic defect or secondary to defective metabolism. They may present as:

- *xanthelasmata*: flat yellow papules around the eyes which can occur both in disorders of cholestasis (ie PBC) and in normolipaemic states
- *eruptive xanthomata*: sudden profuse onset of yellow papules over the buttocks, often associated with triglyceride excess due to uncontrolled diabetes, alcohol excess, oestrogens or, rarely, primary hyperlipidaemia (Fig 5)
- *xanthoma planum*: yellow macules of slightly palpable papules occur in the creases of the hands and are virtually diagnostic of type 3 familial dysbetalipoproteinaemia
- *xanthoma tendinosum*: nodules over the elbows and knees or along tendons (especially the back of the hands and Achilles tendon), often seen in heterozygous familial hypercholesterolaemia
- *diffuse plane xanthomata*: present as widespread yellow/orange patches, chiefly over the trunk and sides of the neck in normolipaemic patients. They can be associated with disorders of the reticuloendothelial system and may precede systemic manifestations by several years. Therefore, careful follow-up is advisable, with periodic laboratory investigations to screen for lymphoproliferative disease.

Pseudoxanthoma elasticum

A rare group of inherited disorders of elastic and collagen fibres, pseudoxanthoma elasticum, manifests as yellow papules and loose thickened skin in the flexures, in combination with ocular and vascular abnormalities (Fig 6). Cracking of Bruch's membrane, resulting in angioid streaks, should be sought by slit-lamp examination of the eyes. Vascular involvement can cause GI or urinary tract haemorrhage, hypertension (through calcification of renal arteries) and angina. A skin biopsy demonstrates fragmentation and clumping of elastic fibres in the mid- and lower dermis.

Ehlers-Danlos syndrome

Ehlers-Danlos syndrome is a group of abnormalities of collagen biosynthesis which result in hyperextensible skin and joints, poor wound healing, easy bruising and occasional fragility of large blood vessels and viscera. Skin is thin, velvety and fragile, heals with tissue paper scars, later becoming pendulous especially over palms and soles. Pseudotumours (herniations of fat through the dermis) are common, particularly over knees and elbows. Serious complications include rupture of a large aneurysm or blood vessel and GI perforation.

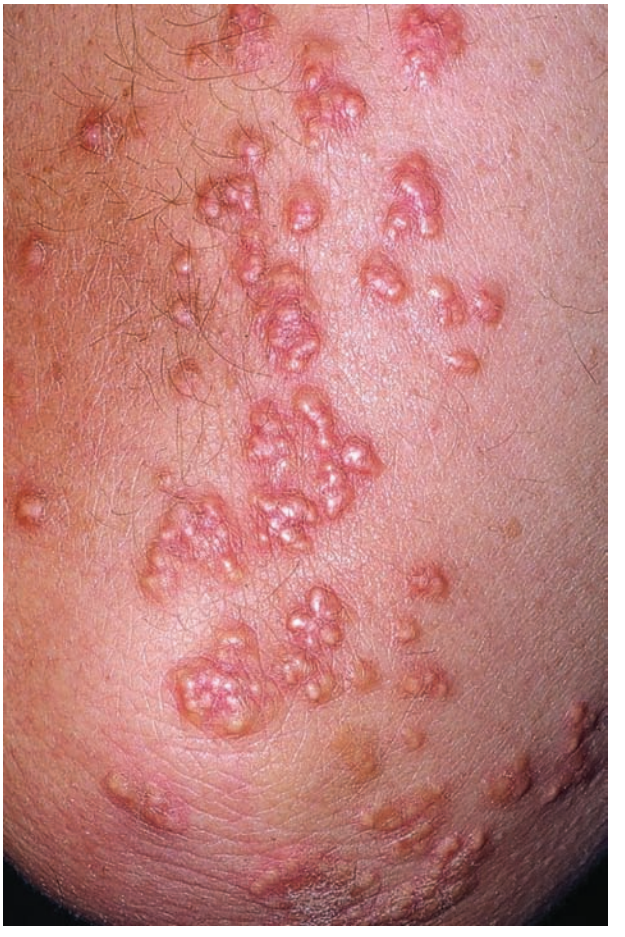

Fig 5. Eruptive xanthomata.

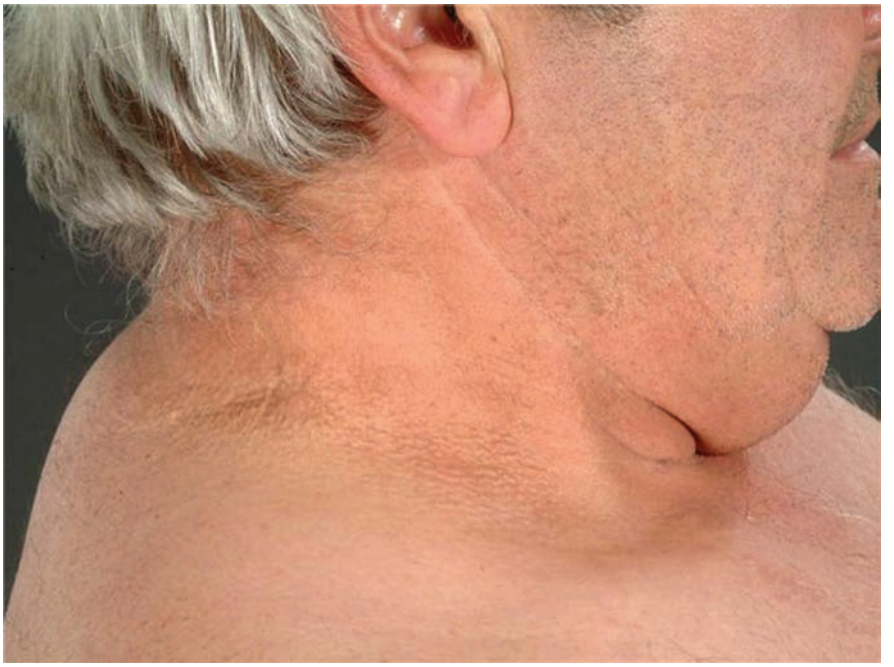

Fig 6. Yellow papules of pseudoxanthoma elasticum.

References

1 Cox NH, Graham RM. Systemic disease and the skin. In: Burns DA, Breathnach SM, Cox NH *et al.* (eds). *Rook's textbook of dermatology* (7th edn). Oxford: Blackwell, 2004.

2 Callen J. Dermatologic signs of systemic diseases. In: Bologna J, Jorizzo JL, Rapini RP (eds). *Dermatology*. St Louis, Mosby, 2003:712–3.

3 Bratton RL, Whiteside JW, Hovan MJ, Engle RL, Edwards FD. Diagnosis and treatment of lyme disease. *Mayo Clin Proc* 2008;83:566–71.

4 Lai-Cheong JE, Perez A, Tang G *et al.* Cutaneous manifestations of tuberculosis. *Clin Exp Dermatol* 2007;32:461–6.

5 Umapathy KC, Begum R, Ravichandran G *et al.* Comprehensive findings on clinical, bacteriological, histopathological and therapeutic aspects of cutaneous tuberculosis. *Trop Med Int Health* 2006;11:1521–8.

6 Alonso-Llamazares J, Gibson LE, Rogers RS 3rd. Clinical, pathologic, and immunopathologic features of dermatitis herpetiformis: review of the Mayo Clinic experience. *Int J Dermatol* 2007;46:910–9.

7 Koulentaki M, Ioannidou D, Stefanidou M et al. Dermatological manifestations in primary biliary cirrhosis patients: a case control study. *Am J Gastroenterol* 2006;101:541–6.

Address for correspondence: Dr S Dhoat, Royal Free Hospital, Pond Street, London NW3 2QG. Email: sasha.dhoat@royalfree.nhs.uk